

Medical Chronology/Summary

Confidential and privileged information

Usage guideline/Instructions

***Verbatim summary:** All the medical details have been included “word by word” or “as it is” from the provided medical records to avoid alteration of the meaning and to maintain the validity of the medical records. The sentence available in the medical record will be taken as it is without any changes to the tense.

***Case synopsis/Flow of events:** For ease of reference and to know the glimpse of the case, we have provided a brief summary including the significant case details.

***Injury report:** Injury report outlining the significant medical events/injuries is provided which will give a general picture of the case.

***Comments:** We have included comments for any noteworthy communications, contradictory information, discrepancies, misinterpretation, missing records, clarifications, etc for your notification and understanding. The comments will appear in red italics as follows:

“*Comments”.

Indecipherable notes/date:** Illegible and missing dates are presented as “00/00/0000” (mm/dd/yyyy format). Illegible handwritten notes are left as a blank space “_____” with a note as ***“Illegible Notes” in heading reference.

***Patient’s History:** Pre-existing history of the patient has been included in the history section.

***Snapshot inclusion:** If the provider name is not decipherable, then the snapshot of the signature is included. Snapshots of significant examinations and pictorial representation have been included for reference.

***De-Duplication:** Duplicate records and repetitive details have been excluded.

General Instructions:

- *The medical summary focuses on C-section performed on 12/23/YYYY, the birth injuries sustained intra-operatively and developmental delays as a result of birth injury, and treatments rendered.*
- *Prenatal records from 05/02/YYYY till 12/20/YYYY have been presented briefly to show the prenatal conditions*
- *Records from 12/22/YYYY till 12/23/YYYY at ABC Health has been presented in a detailed timeline manner*
- *Records from 12/23/YYYY till 01/09/YYYY at Mercy Springfield have been presented in detail*
- *Follow up visits from 01/11/YYYY till 10/21/YYYY have been presented briefly to highlight the developmental delays*
- *Mother records were presented in blue color font and baby records were presented in black color font for ease of differentiation*

Flow of events

ABC Health

05/02/YYYY-12/23/YYYY: Initial OB visit for nausea and vomiting – Diagnosed with nausea/vomiting in pregnancy – Ultrasound revealed intrauterine pregnancy measuring 6 weeks 3 days with EDA 12/23/YYYY.



ABC Health

05/09/YYYY-12/14/YYYY: Multiple prenatal visits for routine prenatal examination, nausea, vomiting – Admitted from 05/17/YYYY to 05/19/YYYY for hyperemesis gravidarum – Prescribed Sertraline for mild depression on 05/25/YYYY - Positive for Group B beta Streptococcus (agalactiae) by PCR on 11/30/YYYY – On final OB visit on 12/14/YYYY, EGA was 38 weeks 4 days, Cervix dilation 1 cm, Cervix effacement 30, Fundal height 38 cm, Fetal station -3, Fetal heart rate 149



ABC Health

12/19/YYYY-12/20/YYYY: Patient presented for Labor and delivery admission at 2335 hours with complaints of contraction – External toco placed, FHR 145, moderate variability, acceleration present, membrane intact – On 12/20/YYYY, at 0057 hours, patient left the facility against medical advice; stated contractions are not as frequent.



ABC Health

12/22/YYYY-12/23/YYYY: At 0956 hours, patient presented with complaints of leaking fluid, abdominal pain and uterine contractions; fluid was bloody, scant and contraction intensity was 10 – External toco placed and monitored – At 1539 hours, admitted to labor and delivery for active labor – Penicillin G potassium started for prophylaxis – On 12/23/YYYY at 0748 hours, planned for C-section due to failure to descend, meconium aspiration – Female baby delivered at 0754 hours - APGARS at 1 min was 1, 5 min was 6, 10 min was 9 – Birth weight was 3090 gm, head circumference 35 cm, birth length 20.5 in – Thick meconium noted in posterior oropharynx and around cords, heart rate dropped and CPR performed for 30 seconds, child stabilized on PPV – At 1745 hours, patient reported baby turned purple, limp and unresponsive – Brought to nursery and intubated with 3.0 ETT after multiple attempts – Noted to have occasional jerky movements of hand – Started on D10 W, Ampicillin and Gentamicin – Transferred to NICU in Springfield at 2117 hours



AB Hospital Springfield

12/23/YYYY-01/09/YYYY: On arrival, ETT was changed with ETT 3.5 mm – UVC and UAC placed at 0017 hours on 12/24/YYYY – Ultrasound of head revealed a small pineal cyst; no evidence of traumatic hemorrhage – Echocardiogram at 0924 hours revealed Small muscular VSD – Admitted with diagnoseid of Respiratory Insufficiency, Meconium Aspiration Syndrome, Sepsis-newborn-suspected, Perinatal depression - Continued on Ampicillin and Gentamicin; Phenobarbital given by transport team for seizure activity – Started on Keppra for seizure and continued with Phenobarbital – EEG revealed focal onset epileptiform seizures noted in both temporal lobes individually suggestive of bilateral onset focal seizures – Continued on SIMV – Extubated on 12/26/YYYY – Feeding started on 12/27/YYYY – Required increased O2 needs placed on High flow nasal canula briefly and back on low flow nasal canula – UAC discontinued

Patient 1
Patient 2

DOB: MM/DD/YYYY
DOB: MM/DD/YYYY

on 12/29/YYYY and transitioned to room air – Antibiotics on 12/30/YYYY – Baby noted with variable tone and activity – MRI of brain revealed findings consistent with anoxic ischemic injury – Ophthalmology consulted for abnormal eye movement; assessed as normal structure and no treatment recommended – Discharged with prescription for Levetiracetam 60 mg and Phenobarbital 12 mg on 01/09/YYYY – Nutrition feeds included Enfamil LIPIL with Fe 24 cal formula



ABC Health

01/11/YYYY: Presented for 2 week Well Child Check (WCC) – No abnormalities noted – Continued on breast milk

01/25/YYYY: Presented for 1 month WCC – Moves all extremities appropriately and no abnormalities noted



ABCD Pediatric Neurology

02/09/YYYY: Patient on Levetiracetam and Phenobarb without side effects – Planned to wean Phenobarbital – advised to continued Keppra 60 mg thrice daily



ABC Health

02/23/YYYY: Presented for 1 month WCC – No focal deficits noted



AB Cardiology

03/23/YYYY: Cardiology consult for ventricular septal defect – Echo revealed VSD – EKG revealed normal sinus rhythm – No intervention recommended for VSD and advised to follow up in 9 months



ABC Health

04/26/YYYY: Presented for 4 month WCC – Weight 4.75 kg – Assessed with weight below third percentile - Noted to have deficit of left eye movement and not turning to the left



XYZ Clinic Smith Glynn Callaway

05/09/YYYY: Ophthalmology consult for eye movement abnormality – Assessed with oculomotor apraxia without head thrusting behavior and intermittent exotropia – No treatment recommended



ABCD Pediatric Neurology

05/23/YYYY: Neurology follow up for seizure medications – Patient was off Phenobarbital since mid-April - Weight 4.99 kg (<1%tile) – Assessed with diffuse cerebral hypoxic/ischemic injury with signs of developmental delay, having a left gaze preference and not using the right arm as much as the left arm -Recommended to continue with Keppra 60 mg



ABC Health

05/31/YYYY: Presented for weight check – Weight 11.06 lb – Assessed with Decreased growth – Advised to increase number of calories in formula feeding



Patient 1
Patient 2

DOB: MM/DD/YYYY
DOB: MM/DD/YYYY

XY Rehabilitation Center

06/15/YYYY: Office visit for visual delays - Not making consistent eye contact and tracking – Recommended direct services from a Teacher of the Visually Impaired (TVI)



ABC Health

06/27/YYYY: Presented for 6 month WCC – Weight 5.37 kg - Weight below the 3rd percentile as well as continued head circumference below the 3rd percentile with weight in the 50th percentile – Recommended to increased formula to 24 cal



XYZ Clinic Smith Glynn Callaway

08/14/YYYY: Ophthalmology follow up for delayed visual maturation – Assessed with intermittent exotropia, Regular astigmatism of both eyes – No treatment recommended



ABC Health

08/15/YYYY-09/06/YYYY: Multiple visits for developmental delay – Weight, head circumference well below the 3rd percentile – Recommended change in concentration in formula



ABCD Pediatric Neurology

09/11/YYYY: No clinical seizure - Weight 5.92 kg – Recommended to continue with Keppra 60 mg



ABC Health

09/13/YYYY: Office visit for low weight and growth delay - Parent reports only taking approximately 5 oz at each feeding – Currently feeding 27 kcal Enfamil 5-6 ounces every 3-4 hours during the day - Recommended some fortification of her solids using fat/protein-heavy cream, coconut oil, avocado



ABC Health

09/27/YYYY-12/05/YYYY: Multiple visits for WCC, failure to thrive – Weight on 12/05/YYYY was 6.2 kg



XYZ Clinic Smith Glynn Callaway

12/11/YYYY: Office Visit for eye misalignment – Complains of eyes drifting out occasionally – Assessed with intermittent exotropia, ocular motor apraxia syndrome – No treatment recommended



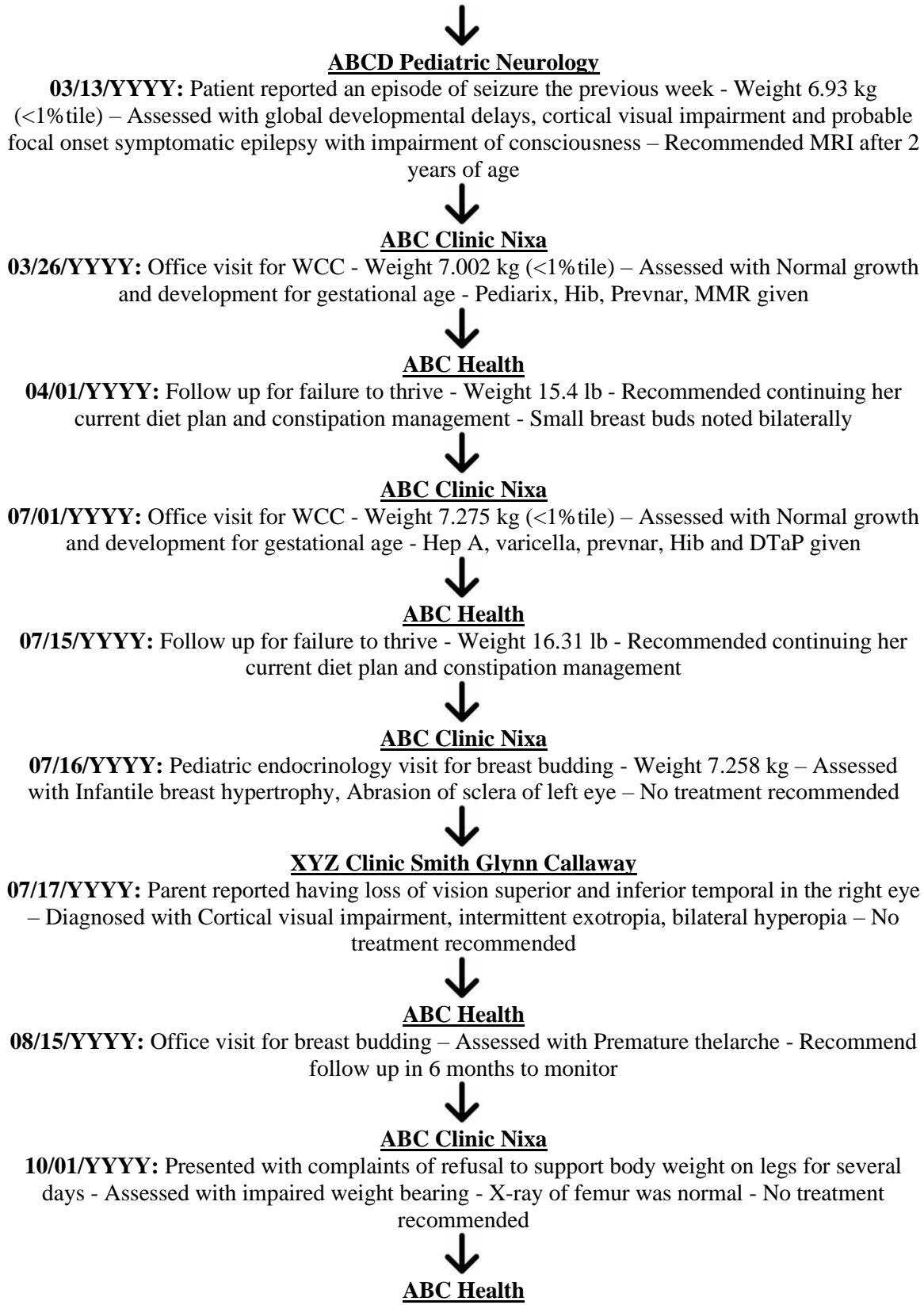
AB Cardiology

12/28/YYYY: Cardiology follow up for VSD – No cardiac symptoms reported and recommended follow up



ABC Health

01/03/YYYY-02/04/YYYY: Multiple visits for well child visit, weight check – Modified barium swallow on 02/04/YYYY revealed mild oral dysphagia and reduced oral motor control and recommended to begin/continue oral diet



Patient 1
Patient 2

DOB: MM/DD/YYYY
DOB: MM/DD/YYYY

10/21/YYYY: Follow up visit for poor weight gain – Weight 17.16 lbs - Poor truncal tone, some early scissoring of lower extremities - Assessed with developmental delay and poor weight gain, tracking below growth curve but gaining steadily

Maternal History

Pregnancy History: G1 P0 (0, 0, 0, 0)

Past Medical History: Allergic rhinitis, Cervical muscle strain, Dysuria, Food allergy, Gastroenteritis, GERD (gastroesophageal reflux disease), headache, IBS (irritable bowel syndrome), Mild depression (Bates Ref: Ex 4 000487, Ex 4 000145)

Surgical History: Non-contributory (Bates Ref: Ex 4 000145)

Family History: Breast cancer, drug abuse, congenital heart defect (Bates Ref: Ex 4 000145, Ex 3 000124)

Social History: History of alcohol usage (1-2 times per year); No history of smoking or drug usage (Bates Ref: Ex 4 000145- Ex 4 000146)

Allergy: No known drug allergies (Bates Ref: Ex 4 000144)

Detailed Summary

| DATE | FACILITY/ PROVIDER | MEDICAL EVENTS | BATES REF |
|------------|-----------------------|--|-----------------------------|
| 05/02/YYYY | Provider/ Hospital | <p>ER visit for nausea and vomiting:</p> <p>Chief Complaint: Vomiting since last night, "nothing stays down"</p> <p>History of Present Illness: The patient presents with nausea and vomiting. Well-appearing, otherwise healthy 27-year-old female, G1 P0 A0, presents to the ER with concerns of nausea and vomiting. Patient tells me she had her last normal period on March 19 and has taken 3 home pregnancy tests which were positive. She tells me that she has had persistent nausea but she became concerned last night when she started to vomit and has had multiple episodes of vomiting. She states she has not been able to keep anything down. She states she started to have abdominal discomfort last night and attributes to soreness from vomiting. She denies vaginal bleeding or discharge, she denies urinary symptoms, she denies fevers, chills or any constitutional symptoms.</p> <p>Notes: Patient states she feels better after 1 L of fluids and Zofran. She is able to tolerate PO fluids. Labs are unremarkable. No evidence of UTI. Ultrasound shows IUP. Patient tells me she is in the process of becoming established with an OB doctor.</p> | Ex 4 000019- Ex 4 000025 |

Patient 1
Patient 2

DOB: MM/DD/YYYY
DOB: MM/DD/YYYY

| DATE | FACILITY/ PROVIDER | MEDICAL EVENTS | BATES REF |
|------------|-----------------------|---|---|
| | | Impression and Plan: Nausea/vomiting in pregnancy Condition: Stable. Disposition: Medically cleared, Discharged. | |
| 05/02/YYYY | Provider/ Hospital | Ultrasound: Clinical History: LMP March 19 th , abdominal pain, vomiting. Impression: Single, viable intrauterine pregnancy measuring 6 weeks 3 days by ultrasound with an estimated date of delivery of 12/23/YYYY. Formal OB ultrasound is recommended at 20-24 weeks gestation for further evaluation of fetal anatomy and placenta. | Ex 4 000092 |
| 05/09/YYYY | Provider/ Hospital | Nursing assessment: Weight: 108.8 lb Pre-pregnancy weight 100 lb Cumulative weight gain 9 lb Height 60 in Antibody screen – Negative Type and Rh interpret – O positive Hepatitis B surface antigen, Hepatitis C antibody, HIV 1/0/2 Ab, RPR qualitative, Rubella IgG Ab – Negative Chlamydia trachomatis, N. gonorrhea – Not detected Urine culture: Normal genitourinary flora | Ex 3 000042- Ex 3 000046, Ex 3 000050- Ex 3 000056 |
| 05/11/YYYY | Provider/ Hospital | ER visit for vomiting: Chief Complaint: Patient complains of nausea, vomiting since around 1100 this morning. Patient states this is more than normal for her. Patient is 8 weeks pregnant. History of Present Illness: There is a formal ultrasound here we are week ago. She presented with vomiting. Vomited one worse in the past 24 hours. This occurred after she ran out of diclegis. She does endorse a bit of mild epigastric pain after vomiting. No difficulty urinating or vaginal bleeding. No fevers and no other acute complaints. Vomiting is worse after eating or drinking. Results review: Interpretation abnormal results during urine, trace ketones. Notes: Patient has a bedside ultrasound for myself, fetal heart tones of 171. Do not see any subchorionic hemorrhage. It is IUP. | Ex 4 000144- Ex 4 000148 |

Patient 1
Patient 2

DOB: MM/DD/YYYY
DOB: MM/DD/YYYY

| DATE | FACILITY/ PROVIDER | MEDICAL EVENTS | BATES REF |
|------------|-----------------------|---|-----------------------------|
| | | <p>Reexamination/re-evaluation: Nausea and vomiting control. Given IV fluids. Patient has had success with likely just previously. We will restart on this. We'll send urine culture. Start on Macrobid.</p> <p>Patient developed recurrent vomiting prior to discharge. I discussed with her at this point option is to Phenergan which made her a bit sleepy, tried Reglan or otherwise try Zofran. I did advise her of the potential risks of Zofran. I feel the risk of cleft palate with 1 dose of Zofran is low. The Phenergan did not make her feel particularly well, suspect she will have similar symptoms with Reglan. She is amenable to trying Zofran. If this doesn't work then will do Reglan.</p> <p>Diagnosis: Asymptomatic bacteriuria of pregnancy Vomiting</p> <p>Prescription: Macrobid 100 mg, Diclegis 10 mg</p> <p>Follow up with Catherine Benbow</p> <p>Condition: Stable, medically cleared, discharged to home.</p> | |
| 05/17/YYYY | Provider/ Hospital | <p>@0958 hours: Office Visit:</p> <p>Chief complaint: Ob new</p> <p><i>Ultrasound reviewed</i> EDD: 12/24/YYYY EGA: 6 weeks 3 days</p> <p>History of Present Illness: Here for new ob. Experiencing a lot of nausea. She has been to the ER twice for nausea/vomiting. She has lost four pounds. Can keep down plain chex cereal. Has used dicligis and it helps some.</p> <p>Assessment/Plan: 1. Supervision of normal pregnancy in first trimester The patient was advised to take a prenatal vitamin. She was advised to avoid any alcohol, drugs or smoking as there is no safe amount in pregnancy. Discussed reasons to call the clinic or go to the ER prior to 20 weeks gestation including vaginal bleeding, cramping, leakage of fluid. Prenatal labs, ultrasound and OB intake form including patient's medical history were reviewed with the patient. Weight gain recommendations in pregnancy were discussed as well as eating healthy small frequent meals throughout the day. Patient's questions and concerns were answered.</p> <p>Ordered: Doxycytamine-pyridoxine, 2 tab</p> | Ex 3 000082- Ex 3 000084 |
| 05/17/YYYY | Provider/ | @1910 hours: ER visit for vomiting: | Ex 4 000237- |

Patient 1
Patient 2

DOB: MM/DD/YYYY
DOB: MM/DD/YYYY

| DATE | FACILITY/ PROVIDER | MEDICAL EVENTS | BATES REF |
|------------|-----------------------|---|-----------------------------|
| | Hospital | <p>Chief Complaint: Vomiting. States she has not held anything down in over 48 hrs. Patient is 8 weeks pregnant. Patient states she has not attempted to take nausea medication and has not taken her antibiotic for UTI.</p> <p>History of Present Illness: Patient is a G1 female who presents today with what appears to be hyperemesis gravidarum. She's been battling vomiting frequently since the onset of first pregnancy starting mid arch. She states she is approximately 8 weeks gestation and was evaluated by her primary care physician this morning. It was found that she had a urinary tract infection and was sent home with antibiotics. She states that she has been unable to keep down her diclegis or her antibiotics. She denies any fever or rashes. She does have some mild abdominal tenderness but she relates it to throwing up frequently. She states her last 48 hours she's not been in to keep any medications down.</p> <p>Medical decision making: Patient presents with continued nausea and vomiting and persistent for the last 48 hours where she is unable to keep down her antibiotics or her routine home medications. She is presently 8 weeks pregnant and is having no problems related to pregnancy. She does have some generalized abdominal discomfort but it is more cramp like associated with persistent vomiting. Her abdomen is soft to palpation. Basic lab work was drawn and showed no acute abnormality. She was given Zofran and failed per oral challenge. She was then given Reglan and failed again. At this point we will have her admitted for continued IV fluids and anti-emetics. Case is also discussed with Dr. De Tar. Dr. Rasmussen agrees to admit.</p> <p>Diagnosis: Hyperemesis of pregnancy</p> <p>Condition: Guarded. Disposition: Admit.</p> | Ex 4 000244 |
| 05/19/YYYY | Provider/ Hospital | <p>Discharge Summary:</p> <p>Admitted: 05/17/YYYY</p> <p>Principal discharge diagnoses:</p> <ol style="list-style-type: none">1. Hyperemesis gravidarum.2. Urinary tract infection.3. Irritable bowel syndrome.4. Gastroesophageal reflux.5. Allergic rhinitis. <p>Hospital Course: We gave her IV antiemetics and fluids. Unfortunately, she was very slow to improve. She ended up staying an additional day, but she was fairly</p> | Ex 4 000215- Ex 4 000217 |

Patient 1
Patient 2

DOB: MM/DD/YYYY
DOB: MM/DD/YYYY

| DATE | FACILITY/ PROVIDER | MEDICAL EVENTS | BATES REF |
|-------------------------------|-----------------------|--|---|
| | | <p>well rehydrated. We decided to change her antiemetic on discharge to oral Promethazine, asked her to continue her prenatal vitamin and that she could continue to take her Diclegis as well. There was some concern about probable depression complicating her course and it was recommended that she follow up with Dr. Benbow regarding this. She was agreeable to do that. She was discharged in much improved condition.</p> <p>Discharge diet: Bland. Discharge activity: Limited. Followup: With Dr. Benbow in 1 week.</p> <p><i>*Reviewer's comment: Only discharge summary was included to show the brief hospitalization events.</i></p> | |
| 05/17/YYYY - 05/19/YYYY | Provider/ Hospital | <p>Others records:</p> <p>Assessment, History and Physical, Patient Education, Nursing Notes/Records, Orders, Medication Sheets, Plan of Care, Labs, Input / Output Record, Discharge Instructions</p> | Ex 4 000218- Ex 4 000236, Ex 4 000245- Ex 4 000266, Ex 4 000297- Ex 4 000467, Ex 4 000269- Ex 4 000296 |
| 05/24/YYYY | Provider/ Hospital | <p>Telephone Conversation regarding lab results</p> <p>Negative pap. Repeat in three years.</p> | Ex 3 000087 |
| 05/25/YYYY | Provider/ Hospital | <p>@0958 hours: Office Visit:</p> <p>Chief complaint: Hospital follow up.</p> <p>EDD: 12/24/YYYY EGA: 9 weeks 4 days</p> <p>History of Present Illness: Was hospitalized for nausea. Feeling better since discharge. Is using more OTC medications that help now and reports some foods she is able to keep down.</p> <p>Assessment/Plan: 1. Supervision of normal pregnancy in first trimester Continue current care of prenatal vitamin, daily mild to moderate physical activity, and frequent small meals throughout the day. Call clinic or go to the ER if you have any vaginal bleeding, leakage or gush of fluid, increasing frequency or intensity of contractions. Return at next scheduled 08 visit in 4 week or sooner if needed. Weight stable today.</p> <p>2. Mild depression: Ordered Sertraline today</p> | Ex 3 000105- Ex 3 000107 |

Patient 1
Patient 2

DOB: MM/DD/YYYY
DOB: MM/DD/YYYY

| DATE | FACILITY/ PROVIDER | MEDICAL EVENTS | BATES REF |
|------------|-----------------------|--|-----------------------------|
| 05/27/YYYY | Provider/ Hospital | <p>ER visit for nausea and vomiting:</p> <p>Chief Complaint: Patient complains of nausea/vomiting all day since 0400. Patient is 10 weeks pregnant. Patient has been taking her nausea/vomiting medication at home with no relief. Patient took Zoloft for the first time last night.</p> <p>History of Present Illness: 27-year-old female G1 PO approximately 10 weeks pregnant per ultrasound here complaining of approximately 12-14 hours of nausea and vomiting. Patient had one episode a week before of significant vomiting that required overnight admission for hydration and medication. Patient states she's felt great the past 5 days and did start Zoloft last night per her doctor. Patient began vomiting at 4 AM this morning and has vomited throughout the day. Patient concerned that Zoloft may have caused the worsening nausea. Patient has no pain, no vaginal bleeding or any other complaints.</p> <p>Reexamination/ Reevaluation: Patient urine unremarkable with some ketones indicating mild dehydration. Patient received 2 L normal saline. Patient also received Reglan, Benadryl and after discussion with her she agreed to a dose of Zofran. Patient has not vomited anymore since first arriving here and is very sleepy. She however still feels mildly nauseous. Bedside ultrasound noted fetal heart rate of 176. Patient like to go home and attempt follow-up with her primary doctor as needed. Patient has Phenergan liquid and diclegis at home. We'll give her a small dose of rectal suppository Phenergan to use as needed.</p> <p>Diagnosis: Nausea and vomiting in pregnancy Dehydration</p> <p>Prescription: Phenergan 12.5 mg rectal suppository</p> <p>Condition: Stable Disposition: Medically cleared. Discharged.</p> <p>Follow up with Catherine Benbow in 3 to 5 days</p> | Ex 4 000485- Ex 4 000490 |
| 05/30/YYYY | Provider/ Hospital | <p>Correspondence regarding pap smear results</p> <p>Pap smear done on 05/17/YYYY was negative (normal)</p> | Ex 3 000080- Ex 3 000081 |
| 06/15/YYYY | Provider/ Hospital | <p>Follow up Visit:</p> <p>Chief complaint: Ob recheck</p> <p>EDD: 12/24/YYYY EGA: 12 weeks 4 days</p> | Ex 3 000123- Ex 3 000125 |

Patient 1
Patient 2

DOB: MM/DD/YYYY
DOB: MM/DD/YYYY

| DATE | FACILITY/ PROVIDER | MEDICAL EVENTS | BATES REF |
|------------|-----------------------|---|-----------------------------|
| | | History of Present Illness: Patient presents to clinic in the 1st trimester for routine prenatal care. Denies vaginal bleeding, leakage of fluid, contractions or cramping. Feeling better; less nausea. Pregnancy complicated by hyperemesis now resolved. Assessment/Plan: 1. Supervision of normal pregnancy in second trimester Continue current care of prenatal vitamin, daily mild to moderate physical activity, and frequent small meals throughout the day. Call clinic or go to the ER if you have any vaginal bleeding, leakage or gush of fluid, increasing frequency or intensity of contractions. Return at next scheduled OB visit in 4 week or sooner if needed. | |
| 07/13/YYYY | Provider/ Hospital | Follow up Visit: Chief complaint: Ob recheck EDD: 12/24/YYYY EGA: 16 weeks 4 days History of Present Illness: Patient presents to clinic in the 2nd trimester for routine prenatal care. Denies vaginal bleeding, leakage of fluid, contractions or cramping. Assessment/Plan: 1. Supervision of normal pregnancy in second trimester Continue current care of prenatal vitamin, daily mild to moderate physical activity, and frequent small meals throughout the day. Call clinic or go to Labor and Delivery Triage at Cox Branson if you have any vaginal bleeding, leakage or gush of fluid, increasing frequency or intensity of contractions or decreased fetal movement. Return at next scheduled OB visit in 4 week or sooner if needed. Discussed genetic screening risks and benefits. She will call with her decision. | Ex 3 000140- Ex 3 000142 |
| 08/08/YYYY | Provider/ Hospital | Ultrasound OB: Clinical History: Supervision of normal pregnancy in second trimester, Encounter for supervision of normal pregnancy, unspecified, second trimester. Heart rate 142 Gender female Estimated fetal weight in grams 350.4 g Estimated fetal weight in pounds and ounces: 0 lb 12 oz Findings: Fetal survey shows a single living intrauterine gestation in the position. The intracranial contents and spine and nose and lips are unremarkable. | Ex 3 000171- Ex 3 000173 |

Patient 1
Patient 2

DOB: MM/DD/YYYY
DOB: MM/DD/YYYY

| DATE | FACILITY/ PROVIDER | MEDICAL EVENTS | BATES REF |
|------------|-----------------------|---|---|
| | | <p>A four-chamber heart is noted in the thorax with normal heart rate, on the same side as the stomach.</p> <p>The kidneys and bladder appear unremarkable.</p> <p>The placenta is and of normal echogenicity. There is adequate amniotic fluid volume and a 3 vessel umbilical cord is identified with normal abdominal and placental cord insertions.</p> <p>Addendum: Fetus is in the vertex position. Placenta is anterior. Fetus composite age 20 weeks 2 days by ultrasound EDC: December 24, 2017</p> | |
| 08/09/YYYY | Provider/ Hospital | <p>Telephone Conversation regarding ultrasound:</p> <p>Normal anatomy scan. Currently breech but plenty of time to change position at this time.</p> | Ex 3 000160, Ex 3 000161- Ex 3 000170 |
| 08/10/YYYY | Provider/ Hospital | <p>Follow up Visit:</p> <p>Chief complaint: Ob recheck</p> <p>EDD: 12/24/YYYY EGA: 20 weeks 4 days Fetal heart rate: 145</p> <p>History of Present Illness: Patient presents to clinic in the 2nd trimester for routine prenatal care. Denies vaginal bleeding, leakage of fluid, contractions, cramping or decreased fetal movement.</p> <p>Physical examination: Uterus: Gravid, size consistent with gestational age.</p> <p>Assessment/Plan: 1. Primigravida in second trimester Continue current care of prenatal vitamin, daily mild to moderate physical activity, and frequent small meals throughout the day. Call clinic or go to Labor and Delivery Triage at Cox Branson if you have any vaginal bleeding, leakage or gush of fluid, increasing frequency or intensity of contractions or decreased fetal movement. Return at next scheduled OB visit in 4 week or sooner if needed.</p> | Ex 3 000185- Ex 3 000188 |
| 09/07/YYYY | Provider/ Hospital | <p>Follow up Visit:</p> <p>Chief complaint: Ob recheck</p> <p>EDD: 12/24/YYYY EGA: 24 weeks 4 days Fetal heart rate: 145</p> | Ex 3 000203- Ex 3 000206 |

Patient 1
Patient 2

DOB: MM/DD/YYYY
DOB: MM/DD/YYYY

| DATE | FACILITY/ PROVIDER | MEDICAL EVENTS | BATES REF |
|------------|-----------------------|---|-----------------------------|
| | | History of Present Illness: Patient presents to clinic in the 2nd trimester for routine prenatal care. Denies vaginal bleeding, leakage of fluid, contractions, cramping or decreased fetal movement. Physical examination: Uterus: Gravid, size consistent with gestational age. Assessment/Plan: 1. Primigravida in second trimester Continue current care of prenatal vitamin, daily mild to moderate physical activity, and frequent small meals throughout the day. Call clinic or go to Labor and Delivery Triage at Cox Branson if you have any vaginal bleeding, leakage or gush of fluid, increasing frequency or intensity of contractions or decreased fetal movement. Return at next scheduled OB visit in 4 week or sooner if needed. | |
| 10/05/YYYY | Provider/ Hospital | Follow up Visit: Chief complaint: Ob recheck EDD: 12/24/YYYY EGA: 28 weeks 4 days Fetal heart rate: 145 History of Present Illness: Patient presents to clinic in the 3rd trimester for routine prenatal care. Denies vaginal bleeding, leakage of fluid, contractions, cramping or decreased fetal movement. Physical examination: Uterus: Gravid, size consistent with gestational age. Assessment/Plan: 1. Primigravida in third trimester Continue current care of prenatal vitamin, daily mild to moderate physical activity, and frequent small meals throughout the day. Call clinic or go to Labor and Delivery Triage at Cox Branson if you have any vaginal bleeding, leakage or gush of fluid, increasing frequency or intensity of contractions or decreased fetal movement. Return at next scheduled OB visit in 2 week or sooner if needed. | Ex 3 000222- Ex 3 000225 |
| 10/05/YYYY | Provider/ Hospital | Telephone Conversation regarding vaccines: LM for patient to return to office, as she left appointment today prior to receiving Tdap & flu vaccines ordered per Dr. Benbow. Message also left with Judy in outpatient lab regarding same related to patient was going to do one hour drip today. | Ex 3 000226- Ex 3 000227 |
| 10/19/YYYY | Provider/ Hospital | Follow up Visit: | Ex 3 000267- Ex 3 000270 |

Patient 1
Patient 2

DOB: MM/DD/YYYY
DOB: MM/DD/YYYY

| DATE | FACILITY/ PROVIDER | MEDICAL EVENTS | BATES REF |
|------------|-----------------------|--|-----------------------------|
| | | <p>Chief complaint: Ob recheck</p> <p>History of Present Illness: Patient presents today for routine prenatal care. She reports she is doing well. She denies any vaginal bleeding, loss of fluid, frequent and painful contractions or decreased fetal movement. Declines flu and TDaP.</p> <p>Assessment/Plan: 1. Pregnant Doing well, continue routine prenatal care. Advised to present to OB triage area for leaking fluid, vaginal bleeding, decreased fetal movement, severe abdominal pain or persistent contractions. Appropriate labs ordered and counseling provided. G1 at 30.4 weeks</p> <p>Encounter for screening examination for impaired glucose regulation and diabetes mellitus. Will obtain 1 hr GTI tomorrow Screening for deficiency anemia. H&H tomorrow Flu, Tdap- declined</p> | |
| 10/20/YYYY | Provider/ Hospital | <p>Labs:</p> <p>Low: Hemoglobin 11.4, hematocrit 33.4 Normal: Glucose 115</p> | Ex 3 000249- Ex 3 000250 |
| 10/21/YYYY | Provider/ Hospital | Telephone Conversation regarding lab results | Ex 3 000247 |
| 11/02/YYYY | Provider/ Hospital | <p>Follow up Visit:</p> <p>Chief complaint: Ob recheck</p> <p>History of Present Illness: Patient presents today for routine prenatal care. She reports she is doing well. She denies any vaginal bleeding, loss of fluid, frequent and painful contractions or decreased fetal movement.</p> <p>Physical examination: Abdomen: Gravid consistent with gestational age. FHT 140</p> <p>Assessment/Plan: 1. Pregnant Doing well, continue routine prenatal care. Advised to present to OB triage area for leaking fluid, vaginal bleeding, decreased fetal movement, severe abdominal pain or persistent contractions. Appropriate labs ordered and counseling provided. G1 at 32.6 weeks</p> | Ex 3 000342- Ex 3 000345 |
| 11/16/YYYY | Provider/ Hospital | <p>Follow up Visit:</p> <p>Chief complaint: Ob recheck</p> | Ex 3 000296- Ex 3 000299 |

Patient 1
Patient 2

DOB: MM/DD/YYYY
DOB: MM/DD/YYYY

| DATE | FACILITY/ PROVIDER | MEDICAL EVENTS | BATES REF |
|------------|-----------------------|---|-----------------------------|
| | | <p>History of Present Illness: Patient presents today for routine prenatal care. She reports she is doing well. She denies any vaginal bleeding, loss of fluid, frequent and painful contractions or decreased fetal movement.</p> <p>Physical examination: Abdomen: Gravid consistent with gestational age. FH 34 FHT 140</p> <p>Assessment/Plan: 1. Pimigravida in third trimester Doing well, continue routine prenatal care. Advised to present to OB triage area for leaking fluid, vaginal bleeding, decreased fetal movement, severe abdominal pain or persistent contractions. Appropriate labs ordered and counseling provided. G1 at 34.4 weeks</p> | |
| 11/30/YYYY | Provider/ Hospital | <p>Follow up Visit:</p> <p>Chief complaint: Ob recheck</p> <p>History of Present Illness: Patient presents today for routine prenatal care. She reports she is doing well. She denies any vaginal bleeding, loss of fluid, frequent and painful contractions or decreased fetal movement. Taking Ranitidine for reflux.</p> <p>Physical examination: Abdomen: Gravid consistent with gestational age. FH 36 FHT 140</p> <p>Assessment/Plan: 1. Pimigravida in third trimester Doing well, continue routine prenatal care. Advised to present to OB triage area for leaking fluid, vaginal bleeding, decreased fetal movement, severe abdominal pain or persistent contractions. Appropriate labs ordered and counseling provided. GBS today. G1 at 36.4 weeks by LMP</p> | Ex 3 000314- Ex 3 000317 |
| 11/30/YYYY | Provider/ Hospital | <p>Genital Strep B screen:</p> <p>Collected date: 11/30/YYYY Source: Vaginal/rectal Specimen positive for Group B beta Streptococcus (agalactiae) by PCR</p> | Ex 3 000373 |
| 12/03/YYYY | Provider/ Hospital | <p>L & D admission assessment:</p> <p>Chief complaint: Back pain, labor check Contraction: Yes</p> | Ex 4 000621- Ex 4 000623 |

Patient 1
Patient 2

DOB: MM/DD/YYYY
DOB: MM/DD/YYYY

| DATE | FACILITY/ PROVIDER | MEDICAL EVENTS | BATES REF |
|------------|-----------------------|---|-----------------------------|
| | | Leaking fluid, bleeding: No Pain: 9 Location: Back, uterine contractions | |
| 12/03/YYYY | Provider/ Hospital | Lab report: 2000 hours: Urinalysis: Leuko esterase 3+, RBC 2-5, WBC 10-20, bacteria 1+, mucous threads 1+ 2108 hours: Urinalysis: Blood 3+, Leuko esterase 2+, RBC 2-5, WBC 5-10, bacteria 1+ | Ex 4 000632- Ex 4 000633 |
| 12/07/YYYY | Provider/ Hospital | Follow up Visit: Chief complaint: Ob recheck History of Present Illness: Patient presents today for routine prenatal care. She reports she is doing well. She denies any vaginal bleeding, loss of fluid, frequent and painful contractions or decreased fetal movement. Taking Ranitidine for reflux. Physical examination: Abdomen: Gravid consistent with gestational age. FH 36 FHT 140 Assessment/Plan: 1. Pimigravida in third trimester Doing well, continue routine prenatal care. Advised to present to OB triage area for leaking fluid, vaginal bleeding, decreased fetal movement, severe abdominal pain or persistent contractions. Appropriate labs ordered and counseling provided. GBS today. G1 at 37.4 weeks by LMP, complicated by GBS + | Ex 3 000400- Ex 3 000403 |
| 12/14/YYYY | Provider/ Hospital | Follow up Visit: Chief complaint: Ob recheck EDD: 12/24/YYYY EGA: 38 weeks 4 days History of Present Illness: Patient presents to clinic in the 3rd trimester for routine prenatal care. Denies vaginal bleeding, leakage of fluid, cramping or decreased fetal movement. Some irregular contractions. Physical examination: Uterus: Gravid, size consistent with gestational age. Cervix dilation: 1 cm Cervix effacement: 30 Fundal height: 38 cm | Ex 3 000382- Ex 3 000385 |

Patient 1
Patient 2

DOB: MM/DD/YYYY
DOB: MM/DD/YYYY

| DATE | FACILITY/ PROVIDER | MEDICAL EVENTS | BATES REF |
|------------|-----------------------|---|---|
| | | Fetal station: -3 Fetal activity: Active Fetal heart rate: 149 Assessment/Plan: 1. Primiparous in third trimester Continue current care of prenatal vitamin, daily mild to moderate physical activity, and frequent small meals throughout the day. Call clinic or go to Labor and Delivery Triage at Cox Branson if you have any vaginal bleeding, leakage or gush of fluid, increasing frequency or intensity of contractions or decreased fetal movement. Return at next scheduled OB visit in 1 week or sooner if needed. | |
| 12/19/YYYY | Provider/ Hospital | @2335 hours: L & D admission assessment: Chief complaint: Contractions, labor check Fetal movement: Present Contraction: Yes Contraction frequency: 2 min Leaking fluid: No Pain: 3, aching, cramping Location: Abdomen Mode of arrival: Wheelchair | Ex 3 000458- Ex 3 000459 |
| 12/19/YYYY | Provider/ Hospital | @2345 hours: Nursing notes: Patient presented to L&D at 2318 with complaints of contractions. EFM and toco placed. External toco placed FHR 145 Moderate variability Accelerations present Membrane – intact | Ex 3 000457- Ex 3 000459, Ex 3 000462- Ex 3 000466 |
| 12/20/YYYY | Provider/ Hospital | Nursing notes: @0015 hours: Patient refused to let an RN check her. Insists that Dr. Jett come in to check her. Explained to patient that the Dr. comes in when necessary after RN evaluates. Patient and spouse still refuse to let me do VE. Uterine contraction frequency: 2-6 Uterine contraction duration: 40-60 @0018 hours: EFM and toco off per patient request. Patient instructed that Dr. Jett does not come in unless necessary and without discharge unless fully evaluated with VE. Patient insists on going home. @0020 hours: Dr. Jett notified of patient refusing to let me do VE. Dr. Jett not coming in for VE, asked to explain to patient that RN does VEs when patient in hospital and notify MD. | Ex 3 000457, Ex 3 000433- Ex 3 000434 |

Patient 1
Patient 2

DOB: MM/DD/YYYY
DOB: MM/DD/YYYY

| DATE | FACILITY/ PROVIDER | MEDICAL EVENTS | BATES REF |
|-------------------------------|-----------------------|---|-----------------------------|
| | | <p>@0030 hours: AMA paper signed by patient after explaining risk to signing such as outside delivery and injury to herself of baby.</p> <p>@0057 hours: Patient verbalized understanding. Stated contractions not as frequent. Discharged home AMA.</p> | |
| 12/21/YYYY | Provider/ Hospital | <p>Follow up Visit:</p> <p>Chief complaint: Ob recheck</p> <p>EDD: 12/24/YYYY EGA: 39 weeks 4 days</p> <p>History of Present Illness: Patient presents to clinic in the 3rd trimester for routine prenatal care. Denies vaginal bleeding, leakage of fluid, cramping or decreased fetal movement. Seen in triage for labor. Still contracting some.</p> <p>Physical examination: Uterus: Gravid, size consistent with gestational age. Cervix dilation: 1 cm Cervix effacement: 70 Fundal height: 39 cm Fetal station: -3 Fetal activity: Active Fetal heart rate: 145</p> <p>Assessment/Plan: 1. Supervision of young primigravida in third trimester Continue current care of prenatal vitamin, daily mild to moderate physical activity, and frequent small meals throughout the day. Call clinic or go to Labor and Delivery Triage at Cox Branson if you have any vaginal bleeding, leakage or gush of fluid, increasing frequency or intensity of contractions or decreased fetal movement. Return at next scheduled OB visit in 1 week or sooner if needed.</p> | Ex 3 000490- Ex 3 000492 |
| 05/02/YYYY - 12/21/YYYY | Provider/ Hospital | <p>Other related records (Prenatal):</p> <p>Assessment, patient education, plan of care, orders, medication sheets, flow sheets</p> <p>Bates Ref: Ex 3 000561-Ex 3 000564, Ex 4 000001- Ex 4 000091, Ex 3 000559, Ex 4 000010- Ex 4 000018, Ex 4 000049, Ex 4 000135-Ex 4 000143, Ex 4 000149-Ex 4 000207, Ex 4 000162, Ex 3 000079, Ex 3 000088-Ex 3 000104, Ex 3 000108-Ex 3 000122, Ex 4 000468-Ex 4 000469, Ex 4 000475-Ex 4 000484, Ex 4 000491-Ex 4 000557, Ex 4 000514, Ex 3 000126-Ex 3 000138, Ex 3 000047, Ex 3 000049, Ex 3 000002, Ex 3 000005-Ex 3 000041, Ex 3 000057-Ex 3 000078, Ex 3 000143-Ex 3 000156, Ex 3 000184, Ex 3 000189-Ex 3 000201, Ex 3</p> | |

Patient 1
Patient 2

DOB: MM/DD/YYYY
DOB: MM/DD/YYYY

| DATE | FACILITY/ PROVIDER | MEDICAL EVENTS | BATES REF |
|--|-----------------------|---|-----------------------------|
| | | 000174, Ex 3 000178-Ex 3 000183, Ex 3 000202, Ex 3 000207-Ex 3 000221, Ex 3 000139, Ex 4 000583-Ex 4 000587, Ex 3 000228-Ex 3 000245, Ex 3 000251- Ex 3 000266, Ex 3 000271-Ex 3 000295, Ex 3 000248, Ex 3 000341, Ex 3 000300-Ex 3 000313, Ex 3 000323-Ex 3 000340, Ex 3 000346-Ex 3 000370, Ex 3 000372, Ex 3 000374-Ex 3 000380, Ex 3 000318-Ex 3 000322, Ex 4 000624-Ex 4 000631, Ex 4 000634-Ex 4 000661, Ex 3 000399, Ex 3 000404-Ex 3 000431, Ex 3 000381, Ex 3 000489, Ex 3 000386-Ex 3 000398, Ex 3 000432, Ex 3 000438-Ex 3 000456, Ex 3 000460- Ex 3 000461, Ex 3 000468-Ex 3 000471, Ex 3 000493-Ex 3 000505 | |
| ABC Health (12/22/YYYY-12/23/YYYY) Labor and delivery | | | |
| 12/22/YYYY | Provider/ Hospital | @0956 hours: Labor & Delivery assessment: Chief complaint: Leaking fluid Reason for visit OB: Abdominal pain, with uterine contractions Fetal movement: Present Last Fetal Movement Date/Time: 12/22/YYYY, 0956 hours Contractions: Yes Contraction Onset Date/Time: 12/22/YYYY, 0500 hours Contraction Frequency (min): Irregular Leaking Fluid: Yes Leaking Fluid Onset Date/Time: 12/22/YYYY, 0500 hours Color/Description of Fluid: Clear, Bloody Bleeding: Yes Bleeding Amount: Scant Pain: Intensity: 10 Location: Uterine contractions Antepartum Risk Factors, Current Pregnancy: Group B Streptococcus | Ex 1 000047- Ex 1 000048 |
| 12/22/YYYY | Provider/ Hospital | @1010 hours: Nursing assessment: Uterine Contraction Monitoring Method: External toco Uterine Contraction Frequency: 4-5 Uterine Contraction Duration: 180-220 Uterine Contraction intensity: Moderate Uterine Contraction rest tone: Soft FHR Monitoring Method: External fetal monitor FHR Baseline: 135 FHR Baseline Variability: Moderate variability FHR Accelerations: Present | Ex 1 000473- Ex 1 000474 |
| 12/22/YYYY | Provider/ Hospital | @1040 hours: Nursing assessment: Uterine Contraction Monitoring Method: External toco Uterine Contraction Frequency: 0.5-4 Uterine Contraction Duration: 160-210 Uterine Contraction intensity: Moderate | Ex 1 000473 |

Patient 1
Patient 2

DOB: MM/DD/YYYY
DOB: MM/DD/YYYY

| DATE | FACILITY/ PROVIDER | MEDICAL EVENTS | BATES REF |
|------------|-----------------------|--|-----------------------------|
| | | Uterine Contraction rest tone: Soft FHR Monitoring Method: External fetal monitor FHR Baseline: 140 FHR Baseline Variability: Moderate variability FHR Accelerations: Present | |
| 12/22/YYYY | Provider/ Hospital | @1055 hours: Nursing assessment: Uterine Contraction Monitoring Method: External toco Uterine Contraction Frequency: 0.5-4 Uterine Contraction Duration: 160-200 Uterine Contraction intensity: Moderate Uterine Contraction rest tone: Soft FHR Monitoring Method: External fetal monitor FHR Baseline: 140 FHR Baseline Variability: Moderate variability FHR Accelerations: Present | Ex 1 000472- Ex 1 000473 |
| 12/22/YYYY | Provider/ Hospital | @1211 hours: Nursing assessment: Cervix dilation: 3 cm Cervix effacement: 50 Fetal station: -2 Bloody show: Yes Cervical consistency: Medium Cervical position: Mid | Ex 1 000472 |
| 12/22/YYYY | Provider/ Hospital | @1240 hours: Nursing assessment: Uterine Contraction Monitoring Method: External toco Uterine Contraction Frequency: 0.5-4 Uterine Contraction Duration: 60-180 Uterine Contraction intensity: Moderate Uterine Contraction rest tone: Soft FHR Monitoring Method: External fetal monitor FHR Baseline: 140 FHR Baseline Variability: Moderate variability FHR Accelerations: Present | Ex 1 000471- Ex 1 000472 |
| 12/22/YYYY | Provider/ Hospital | @1310 hours: Nursing assessment: Uterine Contraction Monitoring Method: External toco Uterine Contraction Frequency: 3-5 Uterine Contraction Duration: 80-110 Uterine Contraction intensity: Moderate Uterine Contraction rest tone: Soft FHR Monitoring Method: External fetal monitor FHR Baseline: 130 FHR Baseline Variability: Moderate variability FHR Accelerations: Present | Ex 1 000471 |
| 12/22/YYYY | Provider/ Hospital | Nursing assessment: | Ex 1 000471 |

Patient 1
Patient 2

DOB: MM/DD/YYYY
DOB: MM/DD/YYYY

| DATE | FACILITY/ PROVIDER | MEDICAL EVENTS | BATES REF |
|------------|-----------------------|---|-------------------------------------|
| | | @1502 hours: Vaginal exam 4, 60, -2 | |
| 12/22/YYYY | Provider/ Hospital | <p>@1539 hours: History and Physical:</p> <p>Chief complaint: Leaking fluid</p> <p>EDD: 12/24/YYYY EGA: 39 week 5 days</p> <p>History of Present Illness: The patient presents with contractions. Patient is</p> <p>Gravida Para Information: Gravida: 1 Para Term: 0 Para Preterm: 0 Para Abortions: 0 Para Living: 0</p> <p>Patient presented to triage with complaints of contractions. In triage over a two hour period she changed to 1.5 to 4 cm and was having painful contractions.</p> <p>Review of systems: Musculoskeletal: Back pain – in the lower region.</p> <p>Current medications: Lactated ringers bolus 1000 ml IV as needed Acetaminophen 650 mg every 6 hours Butorphanol 2 mg inj Citric acid-Sodium citrate 30 ml Hydroxyzine pamoate 50 mg Ibuprofen 800 mg Lidocaine 1% 0.7 ml inj Metoclopramide 10 mg 2 ml inj Ondansetron 4 mg 2 ml inj Penicillin G potassium 2.5 MU 55ml every 4 hours Penicillin G potassium 5 MU 110ml IVPB</p> <p>Vitals at 0951 hours: BP 116/77, pulse 81, resp. rate 18, temp 98.7</p> <p>Obstetric Exam: Singleton/ Baby A fetal evaluation: Fetal movement present, heart tones within normal limits (110 to 160 BPM). Cervix: Membrane status intact.</p> <p>Diagnosis: Carrier of group B Streptococcus. Term pregnancy.</p> | <p>Ex 1 000035- Ex 1 000040</p> |

Patient 1
Patient 2

DOB: MM/DD/YYYY
DOB: MM/DD/YYYY

| DATE | FACILITY/ PROVIDER | MEDICAL EVENTS | BATES REF |
|------------|-----------------------|---|-------------|
| | | Fetal condition: Reassuring fetal heart rate. Maternal condition: Stable. Plan: Admit. Admit for active labor. GBS negative start antibiotics. No AROM until four hours of antibiotics as long as baby continues to have reassuring fetal tracing. Epidural when desired. | |
| 12/22/YYYY | Provider/ Hospital | @1600 hours: Nursing assessment: Uterine Contraction Monitoring Method: External toco Uterine Contraction Frequency: 0.5-4 Uterine Contraction Duration: 60-140 Uterine Contraction rest tone: Soft FHR Monitoring Method: External fetal monitor FHR Baseline: 135 FHR Baseline Variability: Moderate variability FHR Accelerations: Present | Ex 1 000470 |
| 12/22/YYYY | Provider/ Hospital | @1619 hours: Lab report: High: WBC 13.2 Low: Hematocrit 36.0 | Ex 1 000071 |
| 12/22/YYYY | Provider/ Hospital | Nursing assessment: @1623 hours: Obs, admitted for labor | Ex 1 000468 |
| 12/22/YYYY | Provider/ Hospital | @1630 hours: Nursing assessment: Uterine Contraction Monitoring Method: External toco Uterine Contraction Frequency: 0.5-3.5 Uterine Contraction Duration: 60-110 Uterine Contraction rest tone: Soft FHR Monitoring Method: External fetal monitor FHR Baseline: 140 FHR Baseline Variability: Moderate variability FHR Accelerations: Present | Ex 1 000470 |
| 12/22/YYYY | Provider/ Hospital | @1700 hours: Nursing assessment: Uterine Contraction Monitoring Method: External toco Uterine Contraction Frequency: 3.5-4.5 Uterine Contraction Duration: 100-140 Uterine Contraction rest tone: Soft FHR Monitoring Method: External fetal monitor FHR Baseline: 130 FHR Baseline Variability: Moderate variability FHR Accelerations: Present | Ex 1 000469 |
| 12/22/YYYY | Provider/ Hospital | @1705 hours: Nursing assessment: Epidural Patient Position: Sitting on side of bed | Ex 1 000469 |

Patient 1
Patient 2

DOB: MM/DD/YYYY
DOB: MM/DD/YYYY

| DATE | FACILITY/ PROVIDER | MEDICAL EVENTS | BATES REF |
|------------|-----------------------|--|-----------------------------|
| | | Epidural Flow Control Device: Volumetric pump Epidural Placed By: John Driver CRNA Epidural Test Dose Time: 1705 hours Epidural Start: 1713 hours Epidural Bolus, Anesthesia: 1710 hours | |
| 12/22/YYYY | Provider/ Hospital | @1730 hours: Nursing assessment: Uterine Contraction Monitoring Method: External toco Uterine Contraction Frequency: 3.5-4.5 Uterine Contraction Duration: 100-130 Uterine Contraction intensity: Moderate Uterine Contraction rest tone: Soft FHR Monitoring Method: External fetal monitor FHR Baseline: 140 FHR Baseline Variability: Moderate variability FHR Accelerations: Present | Ex 1 000468- Ex 1 000469 |
| 12/22/YYYY | Provider/ Hospital | Nursing assessment: @1730 hours: Vaginal exam 4, 60, -2 @1732 hours: Vaginal exam 4, 60, -2 | Ex 1 000468 |
| 12/22/YYYY | Provider/ Hospital | @1900 hours: Nursing assessment: Uterine Contraction Monitoring Method: External toco Uterine Contraction intensity: Moderate Uterine Contraction rest tone: Soft FHR Monitoring Method: External fetal monitor FHR Baseline: 130 FHR Baseline Variability: Moderate variability FHR Accelerations: Present | Ex 1 000468 |
| 12/22/YYYY | Provider/ Hospital | @1900 hours: Nursing assessment: Uterine Contraction Monitoring Method: External toco Uterine Contraction Frequency: 1.5-4.5 Uterine Contraction Duration: 80-160 Uterine Contraction intensity: Moderate Uterine Contraction rest tone: Soft FHR Monitoring Method: External fetal monitor FHR Baseline: 125 FHR Baseline Variability: Moderate variability FHR Accelerations: Present | Ex 1 000467 |
| 12/22/YYYY | Provider/ Hospital | @1915 hours: Nursing assessment: Uterine Contraction Monitoring Method: External toco Uterine Contraction Frequency: 2.5-3.5 Uterine Contraction Duration: 90-140 Uterine Contraction intensity: Moderate Uterine Contraction rest tone: Soft FHR Monitoring Method: External fetal monitor | Ex 1 000467 |

Patient 1
Patient 2

DOB: MM/DD/YYYY
DOB: MM/DD/YYYY

| DATE | FACILITY/ PROVIDER | MEDICAL EVENTS | BATES REF |
|------------|-----------------------|--|-----------------------------|
| | | FHR Baseline: 140 FHR Baseline Variability: Moderate variability FHR Accelerations: Present | |
| 12/22/YYYY | Provider/ Hospital | @1930 hours: Nursing assessment: Uterine Contraction Monitoring Method: External toco Uterine Contraction Frequency: 1-3 Uterine Contraction Duration: 50-140 Uterine Contraction intensity: Moderate Uterine Contraction rest tone: Soft FHR Monitoring Method: External fetal monitor FHR Baseline: 140 FHR Baseline Variability: Moderate variability FHR Accelerations: Absent | Ex 1 000466 |
| 12/22/YYYY | Provider/ Hospital | Nursing assessment: @1940 hours: Fetal monitoring annotation: Oxytocin rate change to 8 | Ex 1 000466 |
| 12/22/YYYY | Provider/ Hospital | @1945 hours: Nursing assessment: Uterine Contraction Monitoring Method: External toco Uterine Contraction Frequency: 1.5-3 Uterine Contraction Duration: 60-170 Uterine Contraction intensity: Moderate Uterine Contraction rest tone: Soft FHR Monitoring Method: External fetal monitor FHR Baseline: 145 FHR Baseline Variability: Moderate variability FHR Accelerations: Absent FHR deceleration: Early, intermittent Variable deceleration interventions: Continue to evaluate | Ex 1 000465- Ex 1 000466 |
| 12/22/YYYY | Provider/ Hospital | @2000 hours: Nursing assessment: Cervix dilation: 4 cm Cervix effacement: 90 Fetal station: -2 Bloody show: Yes Cervical consistency: Soft Cervical position: Mid Bishop's score: 9 Uterine Contraction Monitoring Method: External toco Uterine Contraction Frequency: 1-2.5 Uterine Contraction Duration: 70-90 Uterine Contraction intensity: Moderate Uterine Contraction rest tone: Soft FHR Monitoring Method: External fetal monitor FHR Baseline: 150 FHR Baseline Variability: Moderate variability FHR Accelerations: Present | Ex 1 000465 |

Patient 1
Patient 2

DOB: MM/DD/YYYY
DOB: MM/DD/YYYY

| DATE | FACILITY/ PROVIDER | MEDICAL EVENTS | BATES REF |
|------------|-----------------------|---|-----------------------------|
| | | FHR deceleration: Variable, intermittent Variable deceleration interventions: Cervical exam, continue to evaluate, turn to right side. | |
| 12/22/YYYY | Provider/ Hospital | @2015 hours: Nursing assessment: Uterine Contraction Monitoring Method: External toco Uterine Contraction Frequency: 1.5-3 Uterine Contraction Duration: 70-90 Uterine Contraction intensity: Moderate Uterine Contraction rest tone: Soft FHR Monitoring Method: External fetal monitor FHR Baseline: 150 FHR Baseline Variability: Moderate variability FHR Accelerations: Present FHR deceleration: Variable, intermittent Variable deceleration interventions: Continue to evaluate | Ex 1 000464 |
| 12/22/YYYY | Provider/ Hospital | @2030 hours: Nursing assessment: Uterine Contraction Monitoring Method: External toco Uterine Contraction Frequency: 1-3 Uterine Contraction Duration: 70-90 Uterine Contraction intensity: Moderate Uterine Contraction rest tone: Soft FHR Monitoring Method: External fetal monitor FHR Baseline: 150 FHR Baseline Variability: Moderate variability FHR Accelerations: Present | Ex 1 000463- Ex 1 000464 |
| 12/22/YYYY | Provider/ Hospital | @2045 hours: Nursing assessment: Uterine Contraction Monitoring Method: External toco Uterine Contraction Frequency: 2-3.5 Uterine Contraction Duration: 90-130 Uterine Contraction intensity: Moderate Uterine Contraction rest tone: Soft FHR Monitoring Method: External fetal monitor FHR Baseline: 150 FHR Baseline Variability: Minimal variability FHR Accelerations: Absent | Ex 1 000463 |
| 12/22/YYYY | Provider/ Hospital | Nursing assessment: @2054 hours: Fetal monitoring annotation: Oxytocin rate change to 12 | Ex 1 000463 |
| 12/22/YYYY | Provider/ Hospital | @2100 hours: Nursing assessment: Uterine Contraction Monitoring Method: External toco Uterine Contraction Frequency: 2-3 Uterine Contraction Duration: 70-150 Uterine Contraction intensity: Moderate Uterine Contraction rest tone: Soft | Ex 1 000462- Ex 1 000463 |

Patient 1
Patient 2

DOB: MM/DD/YYYY
DOB: MM/DD/YYYY

| DATE | FACILITY/ PROVIDER | MEDICAL EVENTS | BATES REF |
|------------|-----------------------|---|-----------------------------|
| | | FHR Monitoring Method: External fetal monitor FHR Baseline: 145 FHR Baseline Variability: Moderate variability FHR Accelerations: Present FHR deceleration: Variable, intermittent Variable deceleration intervention: Continue to evaluate | |
| 12/22/YYYY | Provider/ Hospital | @2115 hours: Nursing assessment: Uterine Contraction Monitoring Method: External toco Uterine Contraction Frequency: 2-2.5 Uterine Contraction Duration: 90-110 Uterine Contraction intensity: Moderate Uterine Contraction rest tone: Soft FHR Monitoring Method: External fetal monitor FHR Baseline: 150 FHR Baseline Variability: Moderate variability FHR Accelerations: Present | Ex 1 000462 |
| 12/22/YYYY | Provider/ Hospital | Nursing assessment: @2122 hours: Fetal monitoring annotation: Oxytocin rate change to 16 | Ex 1 000462 |
| 12/22/YYYY | Provider/ Hospital | @2130 hours: Nursing assessment: Uterine Contraction Monitoring Method: External toco Uterine Contraction Frequency: 1.5-2 Uterine Contraction Duration: 70-100 Uterine Contraction intensity: Moderate Uterine Contraction rest tone: Soft FHR Monitoring Method: External fetal monitor FHR Baseline: 150 FHR Baseline Variability: Moderate variability FHR Accelerations: Absent | Ex 1 000461- Ex 1 000462 |
| 12/22/YYYY | Provider/ Hospital | @2137 hours: Nursing assessment: Cervix dilation: 7 cm Cervix effacement: 100 Fetal station: -2 Bloody show: Yes Cervical consistency: Soft Cervical position: Mid Bishop's score: 10 | Ex 1 000461 |
| 12/22/YYYY | Provider/ Hospital | @2145 hours: Nursing assessment: Uterine Contraction Monitoring Method: External toco Uterine Contraction Frequency: 1-2 Uterine Contraction Duration: 70-120 Uterine Contraction intensity: Moderate Uterine Contraction rest tone: Soft FHR Monitoring Method: External fetal monitor | Ex 1 000460- Ex 1 000461 |

Patient 1
Patient 2

DOB: MM/DD/YYYY
DOB: MM/DD/YYYY

| DATE | FACILITY/ PROVIDER | MEDICAL EVENTS | BATES REF |
|------------|-----------------------|--|-----------------------------|
| | | FHR Baseline: 150 FHR Baseline Variability: Moderate variability FHR Accelerations: Present | |
| 12/22/YYYY | Provider/ Hospital | @2200 hours: Nursing assessment: Uterine Contraction Monitoring Method: External toco Uterine Contraction Frequency: 1-2.5 Uterine Contraction Duration: 70-100 Uterine Contraction intensity: Moderate Uterine Contraction rest tone: Soft FHR Monitoring Method: External fetal monitor FHR Baseline: 150 FHR Baseline Variability: Moderate variability FHR Accelerations: Present | Ex 1 000460 |
| 12/22/YYYY | Provider/ Hospital | Nursing assessment: @2206 hours: Fetal monitoring annotation: Patient vomiting @2212 hours: Fetal monitoring annotation: Anesthesia at bedside | Ex 1 000460 |
| 12/22/YYYY | Provider/ Hospital | @2215 hours: Nursing assessment: Uterine Contraction Monitoring Method: External toco Uterine Contraction Frequency: 1.5 Uterine Contraction Duration: 70 Uterine Contraction intensity: Moderate Uterine Contraction rest tone: Soft FHR Monitoring Method: External fetal monitor FHR Baseline: 155 FHR Baseline Variability: Moderate variability FHR Accelerations: Absent FHR deceleration: Variable, intermittent Variable deceleration interventions: Continue to evaluate | Ex 1 000459- Ex 1 000460 |
| 12/22/YYYY | Provider/ Hospital | @2230 hours: Nursing assessment: Uterine Contraction Monitoring Method: External toco Uterine Contraction Frequency: 1-2 Uterine Contraction Duration: 60-80 Uterine Contraction intensity: Moderate Uterine Contraction rest tone: Soft FHR Monitoring Method: External fetal monitor FHR Baseline: 165 FHR Baseline Variability: Moderate variability FHR Accelerations: Absent FHR deceleration: Variable, intermittent Variable deceleration interventions: Continue to evaluate | Ex 1 000458- Ex 1 000459 |
| 12/22/YYYY | Provider/ Hospital | @2245 hours: Nursing assessment: Uterine Contraction Monitoring Method: External toco Uterine Contraction Frequency: 1-1.5 | Ex 1 000458 |

Patient 1
Patient 2

DOB: MM/DD/YYYY
DOB: MM/DD/YYYY

| DATE | FACILITY/ PROVIDER | MEDICAL EVENTS | BATES REF |
|------------|-----------------------|---|-------------|
| | | Uterine Contraction Duration: 50-80 Uterine Contraction intensity: Moderate Uterine Contraction rest tone: Soft FHR Monitoring Method: External fetal monitor FHR Baseline: 160 FHR Baseline Variability: Moderate variability FHR Accelerations: Present | |
| 12/22/YYYY | Provider/ Hospital | @2300 hours: Nursing assessment: Uterine Contraction Monitoring Method: External toco Uterine Contraction Frequency: 1.5-2 Uterine Contraction Duration: 50-60 Uterine Contraction intensity: Moderate Uterine Contraction rest tone: Soft FHR Monitoring Method: External fetal monitor FHR Baseline: 160 FHR Baseline Variability: Moderate variability FHR Accelerations: Present | Ex 1 000458 |
| 12/22/YYYY | Provider/ Hospital | @2308 hours: Nursing assessment: Cervix dilation: 9 cm Cervix effacement: 100 Fetal station: -2 Bloody show: Yes Cervical consistency: Soft Cervical position: Mid Bishop's score: 10 | Ex 1 000457 |
| 12/22/YYYY | Provider/ Hospital | @2315 hours: Nursing assessment: Uterine Contraction Monitoring Method: External toco Uterine Contraction Frequency: 2-2.5 Uterine Contraction Duration: 90-120 Uterine Contraction intensity: Moderate Uterine Contraction rest tone: Soft FHR Monitoring Method: External fetal monitor FHR Baseline: 155 FHR Baseline Variability: Moderate variability FHR Accelerations: Present | Ex 1 000457 |
| 12/22/YYYY | Provider/ Hospital | @2330 hours: Nursing assessment: Uterine Contraction Monitoring Method: External toco Uterine Contraction Frequency: 1-3.5 Uterine Contraction Duration: 60-140 Uterine Contraction intensity: Moderate Uterine Contraction rest tone: Soft FHR Monitoring Method: External fetal monitor FHR Baseline: 155 FHR Baseline Variability: Moderate variability | Ex 1 000456 |

Patient 1
Patient 2

DOB: MM/DD/YYYY
DOB: MM/DD/YYYY

| DATE | FACILITY/ PROVIDER | MEDICAL EVENTS | BATES REF |
|------------|-----------------------|--|-----------------------------|
| | | FHR Accelerations: Present FHR deceleration: Early, intermittent FHR deceleration intervention: Continue to evaluate | |
| 12/22/YYYY | Provider/ Hospital | Nursing assessment: @2330 hours: Fetal monitoring annotation: Oxytocin rate change to 20 | Ex 1 000456 |
| 12/22/YYYY | Provider/ Hospital | @2345 hours: Nursing assessment: Uterine Contraction Monitoring Method: External toco Uterine Contraction Frequency: 1-2 Uterine Contraction Duration: 60-100 Uterine Contraction intensity: Moderate Uterine Contraction rest tone: Soft FHR Monitoring Method: External fetal monitor FHR Baseline: 145 FHR Baseline Variability: Moderate variability FHR Accelerations: Present FHR deceleration: Early, variable, recurring FHR deceleration intervention: Continue to evaluate | Ex 1 000455- Ex 1 000456 |
| 12/23/YYYY | Provider/ Hospital | @0000 hours: Nursing assessment: Uterine Contraction Monitoring Method: External toco Uterine Contraction Frequency: 1.5-2 Uterine Contraction Duration: 70-80 Uterine Contraction intensity: Moderate Uterine Contraction rest tone: Soft FHR Monitoring Method: External fetal monitor FHR Baseline: 145 FHR Baseline Variability: Moderate variability FHR Accelerations: Present FHR deceleration: Early, recurring FHR deceleration intervention: Continue to evaluate | Ex 1 000453- Ex 1 000454 |
| 12/23/YYYY | Provider/ Hospital | @0010 hours: Nursing assessment: Cervix dilation: 10 cm Cervix effacement: 100 Fetal station: 0 Bloody show: Yes Cervical consistency: Soft Cervical position: Mid Bishop's score: 11 | Ex 1 000454- Ex 1 000455 |
| 12/23/YYYY | Provider/ Hospital | @0030 hours: Nursing assessment: Uterine Contraction Monitoring Method: External toco Uterine Contraction Frequency: 1.5-2.5 Uterine Contraction Duration: 70-100 Uterine Contraction intensity: Moderate Uterine Contraction rest tone: Soft | Ex 1 000453- Ex 1 000454 |

Patient 1
Patient 2

DOB: MM/DD/YYYY
DOB: MM/DD/YYYY

| DATE | FACILITY/ PROVIDER | MEDICAL EVENTS | BATES REF |
|------------|-----------------------|--|-----------------------------|
| | | FHR Monitoring Method: External fetal monitor FHR Baseline: 145 FHR Baseline Variability: Moderate variability FHR Accelerations: Absent FHR deceleration: Early, recurring FHR deceleration intervention: Continue to evaluate | |
| 12/23/YYYY | Provider/ Hospital | @0034 hours: Nursing assessment: Cervix dilation: 10 cm Cervix effacement: 100 Fetal station: 0 Bloody show: Yes Cervical position: Mid Bishop's score: 11 ROM date, time: 12/23/YYYY, 0034 hours Membrane status: Artificial rupture ROM performed by: Catherine Benbow, D.O. ROM confirmed by: Visual pool Amniotic fluid: Small, clear, no odor | Ex 1 000452- Ex 1 000453 |
| 12/23/YYYY | Provider/ Hospital | @0045 hours: Nursing assessment: Uterine Contraction Monitoring Method: External toco Uterine Contraction Frequency: 1.5-2 Uterine Contraction Duration: 50-80 Uterine Contraction intensity: Moderate Uterine Contraction rest tone: Soft FHR Monitoring Method: External fetal monitor FHR Baseline: 150 FHR Baseline Variability: Moderate variability FHR Accelerations: Absent FHR deceleration: Early, recurring FHR deceleration intervention: Continue to evaluate | Ex 1 000451- Ex 1 000452 |
| 12/23/YYYY | Provider/ Hospital | @0100 hours: Nursing assessment: Uterine Contraction Monitoring Method: External toco Uterine Contraction Frequency: 1-2 Uterine Contraction Duration: 70-90 Uterine Contraction intensity: Moderate Uterine Contraction rest tone: Soft FHR Monitoring Method: External fetal monitor FHR Baseline: 150 FHR Baseline Variability: Moderate variability FHR Accelerations: Present FHR deceleration: Early, recurring FHR deceleration intervention: Continue to evaluate | Ex 1 000451 |
| 12/23/YYYY | Provider/ Hospital | @0115 hours: Nursing assessment: Uterine Contraction Monitoring Method: External toco | Ex 1 000450- Ex 1 000451 |

Patient 1
Patient 2

DOB: MM/DD/YYYY
DOB: MM/DD/YYYY

| DATE | FACILITY/ PROVIDER | MEDICAL EVENTS | BATES REF |
|------------|-----------------------|---|-----------------------------|
| | | Uterine Contraction Frequency: 1.5-2 Uterine Contraction Duration: 70-80 Uterine Contraction intensity: Moderate Uterine Contraction rest tone: Soft FHR Monitoring Method: External fetal monitor FHR Baseline: 135 FHR Baseline Variability: Moderate variability FHR Accelerations: Present FHR deceleration: Early, recurring FHR deceleration intervention: Continue to evaluate | |
| 12/23/YYYY | Provider/ Hospital | @0130 hours: Nursing assessment: Uterine Contraction Monitoring Method: External toco Uterine Contraction Frequency: 1-1.5 Uterine Contraction Duration: 60-80 Uterine Contraction intensity: Moderate Uterine Contraction rest tone: Soft FHR Monitoring Method: External fetal monitor FHR Baseline: 135 FHR Baseline Variability: Moderate variability FHR Accelerations: Present FHR deceleration: Early, variable, intermittent FHR deceleration intervention: Cervical exam, continue to evaluate | Ex 1 000450 |
| 12/23/YYYY | Provider/ Hospital | @0131 hours: Nursing assessment: Cervix dilation: 10 cm Cervix effacement: 100 Fetal station: 0 Bloody show: Yes | Ex 1 000449- Ex 1 000450 |
| 12/23/YYYY | Provider/ Hospital | @0145 hours: Nursing assessment: Uterine Contraction Monitoring Method: External toco Uterine Contraction Frequency: 1.5 Uterine Contraction Duration: 50 Uterine Contraction intensity: Moderate Uterine Contraction rest tone: Soft FHR Monitoring Method: External fetal monitor FHR Baseline: 135 FHR Baseline Variability: Moderate variability FHR Accelerations: Present FHR deceleration: Early, intermittent FHR deceleration intervention: Continue to evaluate | Ex 1 000449 |
| 12/23/YYYY | Provider/ Hospital | Nursing assessment: @0155 hours: Fetal monitoring annotation: Repositioned to right side @0157 hours: Fetal monitoring annotation: Oxytocin rate change to 24 | Ex 1 000449 |
| 12/23/YYYY | Provider/ Hospital | @0200 hours: Nursing assessment: | Ex 1 000448 |

Patient 1
Patient 2

DOB: MM/DD/YYYY
DOB: MM/DD/YYYY

| DATE | FACILITY/ PROVIDER | MEDICAL EVENTS | BATES REF |
|------------|-----------------------|---|-----------------------------|
| | | Uterine Contraction Monitoring Method: External toco Uterine Contraction Frequency: 1.5 Uterine Contraction Duration: 70-80 Uterine Contraction intensity: Moderate Uterine Contraction rest tone: Soft FHR Monitoring Method: External fetal monitor FHR Baseline: 135 FHR Baseline Variability: Moderate variability FHR Accelerations: Present FHR deceleration: Early, variable, intermittent FHR deceleration intervention: Continue to evaluate | |
| 12/23/YYYY | Provider/ Hospital | Nursing assessment: @0206 hours: Fetal monitoring annotation: Repositioned to high fowlers @0213 hours: Fetal monitoring annotation: Patient vomiting | Ex 1 000448 |
| 12/23/YYYY | Provider/ Hospital | @0215 hours: Nursing assessment: Uterine Contraction Monitoring Method: External toco Uterine Contraction Frequency: Unable to determine per strip FHR Monitoring Method: External fetal monitor FHR Baseline: 135 FHR Baseline Variability: Moderate variability FHR Accelerations: Present FHR deceleration: Early, intermittent Early deceleration interventions: Continue to evaluate | Ex 1 000448 |
| 12/23/YYYY | Provider/ Hospital | @0230 hours: Nursing assessment: Uterine Contraction Monitoring Method: External toco Uterine Contraction Frequency: 1.5 Uterine Contraction Duration: 70-90 Uterine Contraction intensity: Moderate Uterine Contraction rest tone: Soft FHR Monitoring Method: External fetal monitor FHR Baseline: 150 FHR Baseline Variability: Moderate variability FHR Accelerations: Present | Ex 1 000447 |
| 12/23/YYYY | Provider/ Hospital | Nursing assessment: @0232 hours: Fetal monitoring annotation: Pushing @0237 hours: Fetal monitoring annotation: Pushing | Ex 1 000447 |
| 12/23/YYYY | Provider/ Hospital | @0245 hours: Nursing assessment: Uterine Contraction Monitoring Method: External toco Uterine Contraction Frequency: 1.5 Uterine Contraction Duration: 70-80 Uterine Contraction intensity: Moderate Uterine Contraction rest tone: Soft FHR Monitoring Method: External fetal monitor | Ex 1 000446- Ex 1 000447 |

Patient 1
Patient 2

DOB: MM/DD/YYYY
DOB: MM/DD/YYYY

| DATE | FACILITY/ PROVIDER | MEDICAL EVENTS | BATES REF |
|------------|-----------------------|--|-----------------------------|
| | | FHR Baseline: 135 FHR Baseline Variability: Moderate variability FHR Accelerations: Present FHR deceleration: Early intermittent | |
| 12/23/YYYY | Provider/ Hospital | Nursing assessment: @0247 hours: Fetal monitoring annotation: Pushing @0252 hours: Fetal monitoring annotation: Pushing | Ex 1 000446 |
| 12/23/YYYY | Provider/ Hospital | @0300 hours: Nursing assessment: Uterine Contraction Monitoring Method: External toco Uterine Contraction Frequency: 1.5-2 Uterine Contraction Duration: 50 Uterine Contraction intensity: Moderate Uterine Contraction rest tone: Soft FHR Monitoring Method: External fetal monitor FHR Baseline: 145 FHR Baseline Variability: Moderate variability FHR Accelerations: Present FHR deceleration: Early Recurring Early deceleration interventions: Continue to evaluate | Ex 1 000445- Ex 1 000446 |
| 12/23/YYYY | Provider/ Hospital | Nursing assessment: @0302 hours: Fetal monitoring annotation: Pushing @0307 hours: Fetal monitoring annotation: Pushing | Ex 1 000445 |
| 12/23/YYYY | Provider/ Hospital | @0315 hours: Nursing assessment: Uterine Contraction Monitoring Method: External toco Uterine Contraction Frequency: 1.5 Uterine Contraction Duration: 70-80 Uterine Contraction intensity: Moderate Uterine Contraction rest tone: Soft FHR Monitoring Method: External fetal monitor FHR Baseline: 135 FHR Baseline Variability: Moderate variability FHR Accelerations: Present FHR deceleration: Recurring Early deceleration interventions: Continue to evaluate | Ex 1 000444- Ex 1 000445 |
| 12/23/YYYY | Provider/ Hospital | @0315 hours: Nursing assessment: FHR deceleration: Early | Ex 1 000444 |
| 12/23/YYYY | Provider/ Hospital | Nursing assessment: @0317 hours: Fetal monitoring annotation: Pushing @0322 hours: Fetal monitoring annotation: Pushing | Ex 1 000443 |
| 12/23/YYYY | Provider/ Hospital | @0330 hours: Nursing assessment: Uterine Contraction Monitoring Method: External toco | Ex 1 000443- Ex 1 000444 |

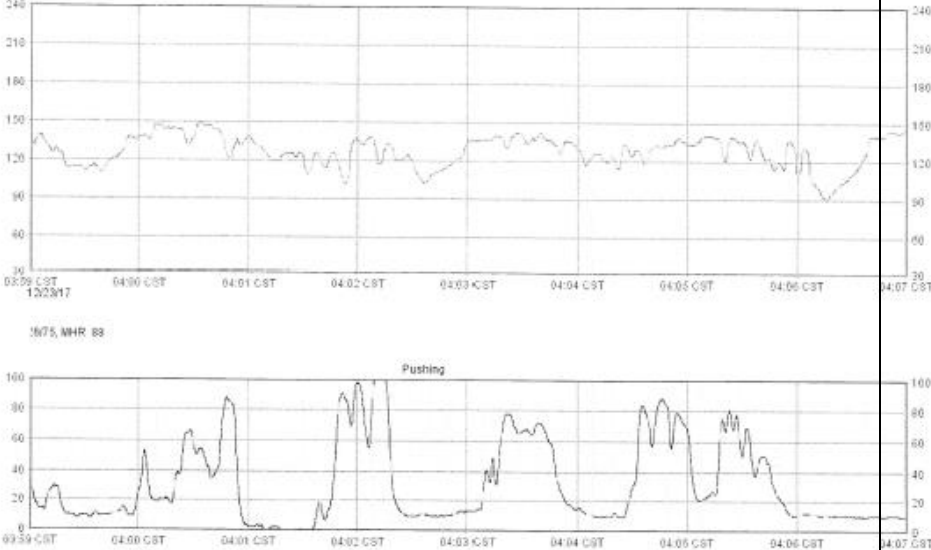
Patient 1
Patient 2

DOB: MM/DD/YYYY
DOB: MM/DD/YYYY

| DATE | FACILITY/ PROVIDER | MEDICAL EVENTS | BATES REF |
|------------|-----------------------|---|-----------------------------|
| | | Uterine Contraction Frequency: 1.5 Uterine Contraction Duration: 70-80 Uterine Contraction intensity: Moderate Uterine Contraction rest tone: Soft FHR Monitoring Method: External fetal monitor FHR Baseline: 130 FHR Baseline Variability: Moderate variability FHR Accelerations: Present FHR deceleration: Early, recurring Early deceleration interventions: Continue to evaluate | |
| 12/23/YYYY | Provider/ Hospital | Nursing assessment: @0332 hours: Fetal monitoring annotation: Pushing @0337 hours: Fetal monitoring annotation: Pushing | Ex 1 000443 |
| 12/23/YYYY | Provider/ Hospital | @0345 hours: Nursing assessment: Uterine Contraction Monitoring Method: External toco Uterine Contraction Frequency: 1.5-2 Uterine Contraction Duration: 60-80 Uterine Contraction intensity: Moderate Uterine Contraction rest tone: Soft FHR Monitoring Method: External fetal monitor FHR Baseline: 130 FHR Baseline Variability: Moderate variability FHR Accelerations: Present FHR deceleration: Early, recurring Early deceleration interventions: Continue to evaluate | Ex 1 000442- Ex 1 000443 |
| 12/23/YYYY | Provider/ Hospital | Nursing assessment: @0347 hours: Fetal monitoring annotation: Pushing @0352 hours: Fetal monitoring annotation: Pushing | Ex 1 000442 |
| 12/23/YYYY | Provider/ Hospital | @0402 hours: Nursing assessment: Uterine Contraction Monitoring Method: External toco Uterine Contraction Frequency: 1.5 Uterine Contraction Duration: 60-70 Uterine Contraction intensity: Moderate Uterine Contraction rest tone: Soft FHR Monitoring Method: External fetal monitor FHR Baseline: 130 FHR Baseline Variability: Moderate variability FHR Accelerations: Present FHR deceleration: Early, late, intermittent Early deceleration interventions: Continue to evaluate | Ex 1 000441- Ex 1 000442 |
| 12/23/YYYY | Provider/ Hospital | Fetal Monitoring strips: | Ex 1 000698 |

Patient 1
Patient 2

DOB: MM/DD/YYYY
DOB: MM/DD/YYYY

| DATE | FACILITY/ PROVIDER | MEDICAL EVENTS | BATES REF |
|------------|-----------------------|--|-------------|
| | |  <p><i>*Reviewer's comment: Monitoring strips corresponding to late decelerations alone have been presented.</i></p> | |
| 12/23/YYYY | Provider/ Hospital | <p>@0415 hours: Nursing assessment:</p> <p>Uterine Contraction Monitoring Method: External toco Uterine Contraction Frequency: 1.5-2 Uterine Contraction Duration: 50-60 Uterine Contraction intensity: Moderate Uterine Contraction rest tone: Soft FHR Monitoring Method: External fetal monitor FHR Baseline: 130 FHR Baseline Variability: Moderate variability FHR Accelerations: Present FHR deceleration: Early, late, intermittent Early deceleration interventions: Continue to evaluate</p> | Ex 1 000441 |
| 12/23/YYYY | Provider/ Hospital | <p>Fetal Monitoring Strips:</p> | Ex 1 000699 |

Patient 1
Patient 2

DOB: MM/DD/YYYY
DOB: MM/DD/YYYY

| DATE | FACILITY/ PROVIDER | MEDICAL EVENTS | BATES REF |
|------------|-----------------------|--|-------------|
| | | | |
| 12/23/YYYY | Provider/ Hospital | @0426 hours: Nursing assessment: Fetal monitoring annotation: Pushing Oxytocin rate change to 28 | Ex 1 000444 |
| 12/23/YYYY | Provider/ Hospital | @0430 hours: Nursing assessment: Uterine Contraction Monitoring Method: External toco Uterine Contraction Frequency: 1.5 Uterine Contraction Duration: 50-60 Uterine Contraction intensity: Moderate Uterine Contraction rest tone: Soft FHR Monitoring Method: External fetal monitor FHR Baseline: 130 FHR Baseline Variability: Moderate variability FHR Accelerations: Present FHR deceleration: Intermittent Early deceleration interventions: Continue to evaluate | Ex 1 000440 |
| 12/23/YYYY | Provider/ Hospital | @0445 hours: Nursing assessment: Uterine Contraction Monitoring Method: External toco Uterine Contraction Frequency: 2 Uterine Contraction Duration: 50 Uterine Contraction intensity: Moderate Uterine Contraction rest tone: Soft FHR Monitoring Method: External fetal monitor FHR Baseline: 130 FHR Baseline Variability: Moderate variability FHR Accelerations: Present | Ex 1 000440 |
| 12/23/YYYY | Provider/ Hospital | @0451 hours: Nursing assessment: Oxytocin rate change to 32 | Ex 1 000439 |

Patient 1
Patient 2

DOB: MM/DD/YYYY
DOB: MM/DD/YYYY

| DATE | FACILITY/ PROVIDER | MEDICAL EVENTS | BATES REF |
|------------|-----------------------|--|--------------|
| 12/23/YYYY | Provider/ Hospital | @0500 hours: Nursing assessment: Uterine Contraction Monitoring Method: External toco Uterine Contraction Frequency: 1.5 Uterine Contraction Duration: 40 FHR Monitoring Method: External fetal monitor FHR Baseline: 130 FHR Baseline Variability: Moderate variability FHR Accelerations: Present | Ex 1 000439 |
| 12/23/YYYY | Provider/ Hospital | @0515 hours: Nursing assessment: Uterine Contraction Monitoring Method: External toco Uterine Contraction Frequency: Indeterminate due to toco placement Uterine Contraction Duration: 60 FHR Monitoring Method: External fetal monitor FHR Baseline: 130 FHR Baseline Variability: Moderate variability FHR Accelerations: Present FHR deceleration: Early, intermittent | Ex 1 000439 |
| 12/23/YYYY | Provider/ Hospital | @0530 hours: Nursing assessment: Uterine Contraction Monitoring Method: External toco Uterine Contraction Frequency: 1.5 Uterine Contraction Duration: 60 FHR Monitoring Method: External fetal monitor FHR Baseline: 130 FHR Baseline Variability: Moderate variability FHR Accelerations: Present | Ex 1 000438 |
| 12/23/YYYY | Provider/ Hospital | @0545 hours: Nursing assessment: Uterine Contraction Monitoring Method: External toco Uterine Contraction Frequency: 1.5 Uterine Contraction Duration: 60 FHR Monitoring Method: External fetal monitor FHR Baseline: 140 FHR Baseline Variability: Moderate variability FHR Accelerations: Present | Ex 1 000438 |
| 12/23/YYYY | Provider/ Hospital | @0600 hours: Nursing assessment: Uterine Contraction Monitoring Method: External toco Uterine Contraction Frequency: Indeterminate tracing due to toco positioning Uterine Contraction Duration: 80-100 FHR Monitoring Method: External fetal monitor FHR Baseline: 160 FHR Baseline Variability: Minimal variability FHR Accelerations: Present | Ex 1 000437 |
| 12/23/YYYY | Provider/ | @0615 hours: Nursing assessment: | Ex 1 000436- |

Patient 1
Patient 2

DOB: MM/DD/YYYY
DOB: MM/DD/YYYY

| DATE | FACILITY/ PROVIDER | MEDICAL EVENTS | BATES REF |
|------------|-----------------------|---|-----------------------------|
| | Hospital | Uterine Contraction Monitoring Method: External toco Uterine Contraction Frequency: 2-4 Uterine Contraction Duration: 80-100 Uterine Irritability: No Uterine Contraction Intensity, Ext Palp: Strong Uterine Contraction Rest Tone, Ext Palp: Soft Uterine Contractions Perceived by patient: Yes Patient Position, OB: Left lateral FHR Monitoring Method: External fetal monitor FHR Baseline: 170 FHR Baseline Variability: Minimal variability FHR Accelerations: Absent FHR Deceleration: Early FHR Deceleration Description: Intermittent Early Deceleration Interventions: Continue to evaluate | Ex 1 000437 |
| 12/23/YYYY | Provider/ Hospital | @0630 hours: Nursing assessment: Uterine Contraction Monitoring Method: External toco Uterine Contraction Frequency: 3 Uterine Contraction Duration: 80-90 Uterine Irritability: No Uterine Contraction Intensity, Ext Palp: Moderate Uterine Contraction Rest Tone, Ext Palp: Soft Uterine Contractions Perceived by patient: Yes Patient Position, OB: Left lateral FHR Monitoring Method: External fetal monitor FHR Baseline: 180 FHR Baseline Variability: Minimal variability FHR Accelerations: Absent FHR Deceleration: Early FHR Deceleration Description: Intermittent Early Deceleration Interventions: Continue to evaluate | Ex 1 000436 |
| 12/23/YYYY | Provider/ Hospital | @0645 hours: Nursing assessment: Uterine Contraction Monitoring Method: External toco Uterine Contraction Frequency: 1.5-2.5 Uterine Contraction Duration: 80-90 Uterine Irritability: No Uterine Contraction Intensity, Ext Palp: Moderate Uterine Contraction Rest Tone, Ext Palp: Soft Uterine Contractions Perceived by patient: Yes Patient Position, OB: Right lateral FHR Monitoring Method: External fetal monitor FHR Baseline: 175 FHR Baseline Variability: Minimal variability FHR Accelerations: Absent FHR Deceleration: Early | Ex 1 000435- Ex 1 000436 |

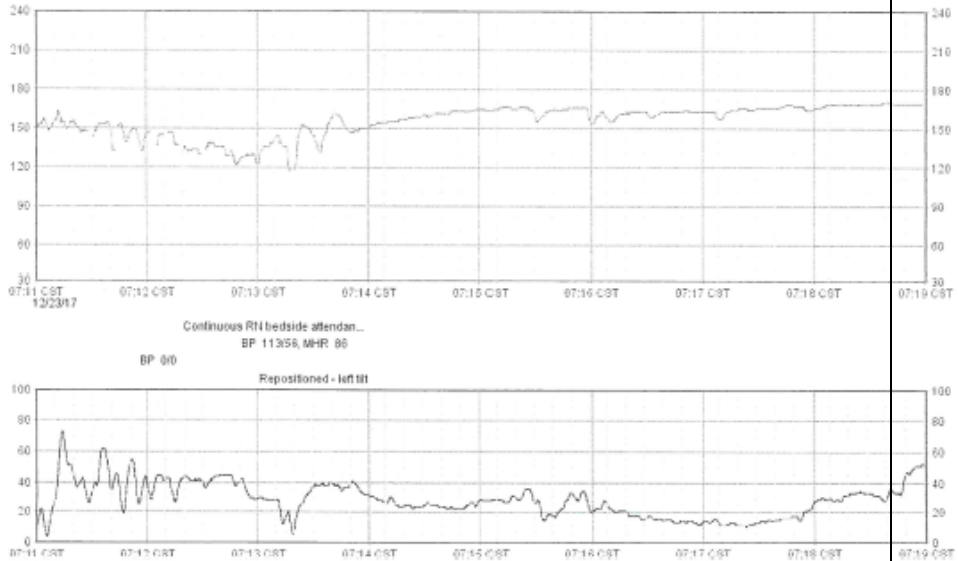
Patient 1
Patient 2

DOB: MM/DD/YYYY
DOB: MM/DD/YYYY

| DATE | FACILITY/ PROVIDER | MEDICAL EVENTS | BATES REF |
|------------|-----------------------|--|-------------|
| | | FHR Deceleration Description: Intermittent Early Deceleration Interventions: Continue to evaluate | |
| 12/23/YYYY | Provider/ Hospital | @0700 hours: Nursing assessment: Uterine Contraction Monitoring Method: External toco Uterine Contraction Frequency: 1.5-2.5 Uterine Contraction Duration: 80-90 Uterine Irritability: No Uterine Contraction Intensity, Ext Palp: Moderate Uterine Contraction Rest Tone, Ext Palp: Soft Uterine Contractions Perceived by patient: Yes Patient Position, OB: Left lateral FHR Monitoring Method: External fetal monitor FHR Baseline: 175 FHR Baseline Variability: Minimal variability FHR Accelerations: Absent FHR Deceleration: Early FHR Deceleration Description: Intermittent Early Deceleration Interventions: Continue to evaluate | Ex 1 000435 |
| 12/23/YYYY | Provider/ Hospital | @0715 hours: Nursing assessment: Uterine Contraction Monitoring Method: External toco Uterine Contraction Frequency: 2-3 Uterine Contraction Duration: 80-90 Uterine Irritability: No Uterine Contraction Intensity, Ext Palp: Moderate Uterine Contraction Rest Tone, Ext Palp: Soft Uterine Contractions Perceived by patient: Yes Patient Position, OB: Left tilt FHR Monitoring Method: External fetal monitor FHR Baseline: 175 FHR Baseline Variability: Minimal variability FHR Accelerations: Absent FHR Deceleration: Early, late FHR Deceleration Description: Intermittent Early Deceleration Interventions: Continue to evaluate Late Deceleration Interventions: Increase IV fluids, notify primary health provider, left tilt | Ex 1 000434 |
| 12/23/YYYY | Provider/ Hospital | Fetal Monitoring strips: | Ex 1 000722 |

Patient 1
Patient 2

DOB: MM/DD/YYYY
DOB: MM/DD/YYYY

| DATE | FACILITY/ PROVIDER | MEDICAL EVENTS | BATES REF |
|------------|-----------------------|---|--|
| | |  | |
| 12/23/YYYY | Provider/ Hospital | <p>@0725 hours: Nursing assessment:</p> <p>Uterine Contraction Monitoring Method: External toco Uterine Contraction Frequency: 1.5-2.5 Uterine Contraction Duration: 80-90 Uterine Irritability: No Uterine Contraction Intensity, Ext Palp: Moderate Uterine Contraction Rest Tone, Ext Palp: Soft Uterine Contractions Perceived by patient: Yes Patient Position, OB: Left tilt FHR Monitoring Method: External fetal monitor FHR Baseline: 170 FHR Baseline Variability: Minimal variability FHR Accelerations: Absent</p> | Ex 1 000433 |
| 12/23/YYYY | Provider/ Hospital | <p>@0748 hours: Operative Report:</p> <p>Preoperative diagnoses:</p> <ol style="list-style-type: none"> 1. Pregnancy, single, 39.6 week gestational age. 2. Failure to Descend 3. GBS Positive <p>Postoperative diagnoses:</p> <ol style="list-style-type: none"> 1. Pregnancy, single, 39.6 week gestational age. 2. Failure to Descend 3. Meconium 4. GBS Positive <p>Patient is a G1 who became complete and began pushing at 0 station. She descended to +1 station in the first 1.5 hours of pushing and then did not make any progress for another 1.5 hours. Despite stopping her epidural anesthesia and adequate contractions she failed to progress. It was</p> | <p>Ex 1 000071- Ex 1 000072, Ex 1 000061- Ex 1 000066, Ex 1 000002- Ex 1 000014</p> |

Patient 1
Patient 2

DOB: MM/DD/YYYY
DOB: MM/DD/YYYY

| DATE | FACILITY/ PROVIDER | MEDICAL EVENTS | BATES REF |
|------|-----------------------|--|-----------|
| | | <p>determined to proceed with C-section. The risks of bleeding, infection and injury to surrounding structures were explained. The patient and family wished to proceed.</p> <p>Operation: Primary low segment transverse cesarean section.</p> <p>Anesthesia: Spinal.</p> <p>Description of procedure: After assuring informed consent, the patient was taken to the operating room, spinal anesthesia was initiated. Foley catheter was placed prior to beginning the procedure. The patient was placed in dorsal supine position with lateral tilt. Abdomen was prepped and draped in sterile fashion. 2 grams of Ancef and 500 mg Azithromycin IV were given just prior to the incision. Pfannenstiel skin incision was made with a scalpel and carried through to the level of the fascia.</p> <p>Fascial incision was then extended bilaterally with Mayo scissors. Fascial incision was then grasped with Kocher clamps, elevated and dissected superiorly and inferiorly from the rectus muscles, both bluntly and sharply. Rectus muscles were then separated in the midline until the peritoneum was reached. Peritoneum was entered bluntly and then extended superiorly and inferiorly bluntly. Bladder blade was then inserted to protect the bladder. The lower uterine segment was identified and incised in a transverse fashion with a scalpel and extended bluntly in elliptical fashion. Bladder blade was removed and the infant was delivered through the hysterotomy incision with some difficulty bringing the head to the level of the incision. Nose and mouth were suctioned, cord was clamped and cut. The infant was handed off to the recovery team. Arterial and venous blood samples were obtained. Cord blood was sent. Placenta was then removed after spontaneous separation. Uterus was then exteriorized and cleared of all clots. The uterine incision was repaired with 1 chromic gut in a running fashion and a second embricating layer was added using 1 chromic in a running fashion. Hemostasis was obtained.</p> <p>Uterus was returned to the abdomen. Fascia was reapproximated with 0 Vicryl in a running fashion. The skin was then closed with 4-0 Vicryl. The patient tolerated the procedure well. Needle and sponge counts were correct times 2. Sterile dressing was placed over the incision.</p> <p>The patient delivered a term female viable infant in cephalic presentation. Fluid was clear. No nuchal cord was present. Apgars were 1 at 1 minute, 6 at 5 minutes 9 at 10 minutes. Birth weight was 3090 g, which is 6 pounds 13 ounces. Cord pH was 7.13. Estimated blood loss was 800 ml secondary to normal surgical losses. Specimens of the placenta, cord pH, cord blood specimens were sent. Foley drainage was blood tinged prior to procedure and noted to be the same afterwards. No complications were noted. The patient tolerated the procedure well and transferred to recovery room in stable condition.</p> | |

Patient 1
Patient 2

DOB: MM/DD/YYYY
DOB: MM/DD/YYYY

| DATE | FACILITY/ PROVIDER | MEDICAL EVENTS | BATES REF |
|-------------------------------|-----------------------|---|-----------------------------|
| 12/22/YYYY - 12/23/YYYY | Provider/ Hospital | Fetal Monitoring Strips <i>*Reviewer's comment: Fetal monitoring strips were reviewed and snapshots corresponding to late deceleration alone have been presented in appropriate timeline.</i> | Ex 1 000543- Ex 1 000791 |
| 12/23/YYYY | Provider/ Hospital | @0758 hours: Nursing notes: Dr. Rasmussen deep suctioning with delee suction catheter; neonate lacks tone or effort. Roll placed under shoulder to place neonate in a sniffing position. | Ex 2 001047, Ex 2 001020 |
| 12/23/YYYY | Provider/ Hospital | @0800 hours: Nursing assessment: ROM to delivery total time: 440 min Membrane status: Artificial rupture ROM performed by: Catherine Benbow, D.O. ROM confirmed by: Visual pool Amniotic fluid amount: Small Amniotic fluid color: Clear Labor onset methods: Spontaneous, augmented Augmentation methods: Oxytocin infusion Birth position: Supine with hip roll Infant delivery position: Vertex Date time of birth: 12/23/YYYY, 0754 hours Delivery type: C-section Reason for C-section: Lack of descent of fetal head Gender: Female Neonate outcome: Live birth, singleton Suction: Catheter pharynx Suction catheter pressure: 100 mmHg Sputum amount: Moderate Sputum color: Green, yellow Sputum consistency: Tenacious Apgar 1 min: 1 Apgar 5 min: 6 Apgar 10 min: 9 Cord blood sent to lab: Yes Birth weight: 3.090 kg (6 lb) Birth length: 20.5 in (52.07 cm) Birth head circumference: 35 cm | Ex 1 000430 |
| 12/23/YYYY | Provider/ Hospital | Nursing notes: @0802 hours: Neonate showing some tone/flexion @0804 hours: Neonate has weak cry and some tone @0805 hours: Neonate is exhibiting a weak cry @0807 hours: Weak cry; Dr. Rasmussen remains at cribside to perform suctioning | Ex 2 001046- Ex 2 001047 |

Patient 1
Patient 2

DOB: MM/DD/YYYY
DOB: MM/DD/YYYY

| DATE | FACILITY/ PROVIDER | MEDICAL EVENTS | BATES REF |
|------------|-----------------------|---|-----------------------------|
| 12/23/YYYY | Provider/ Hospital | @0808 hours: Lab report: High: Glucose 128 | Ex 2 000940 |
| 12/23/YYYY | Provider/ Hospital | Nursing notes: @0809 hours: Neonate exhibiting moderate tone and weak cries | Ex 2 001046 |
| 12/23/YYYY | Provider/ Hospital | @0815 hours: Newborn admission assessment: Time Placed in Bed: 12/23/YYYY, 0754 hours Birth Weight: 3.090 kg Maternal Hep B Surface Antigen: Negative Hepatitis B Vaccine Needed: Yes Hepatitis B Immune Globulin Needed: No Newborn Nutritional Screen: None Plan for Feedings: Breast milk & formula Skin risk assessment: Braden Score Calculation: 24 Gestational Age At Birth: 279 days | Ex 2 000918- Ex 2 000919 |
| 12/23/YYYY | Provider/ Hospital | @0815 hours: Nursing assessment: Level of consciousness: Active with stimulation Muscle tone: Hypotonic Respiratory effort: Easy, regular Bilateral upper breath sounds: Rubbing Skin: Normal for ethnicity, pink, acrocyanosis Vitals: Pulse 162, resp. rate 48, temp 97.8, SpO2 99% Neurologic reflexes: Gag, rooting, sucking, Babinski, blink Cry: Grunty ROM extremities: Full ROM | Ex 2 001014- Ex 2 001015 |
| 12/23/YYYY | Provider/ Hospital | @0821 hours: Resuscitation Note: I was called to attend to the birth of infant female who had to be delivered by C-section after concerns of failure to progress. There had been no significant issues with the pregnancy other than hyperemesis gravidum. The mother is a 28-year-old G1 now P1 at 39 1/2 weeks. The infant was delivered by urgent C-section. The infant had no respiratory effort initially and thick meconium was noted upon rupture of membranes at delivery. The infant was taken immediately to the radiant warmer. Stimulation and suction immediately. APGAR was 1 at one minute. Laryngoscope used to visual cords and suction very thick meconium from posterior oropharynx and around the cords. Heart dropped just prior to this requiring brief (30 seconds of CPR). This CPR was able to discontinued rapidly and infant began to cry. Ongoing suction and PPV were administered. APGAR at 5 minutes was 6. The infant had a blood sugar obtained that was 128 mg/dl. Ongoing resuscitation performed and APGAR at 10 minutes was recorded as 8. Blow by oxygen is continued to be provided to keep oxygen up in | Ex 2 000920 |

Patient 1
Patient 2

DOB: MM/DD/YYYY
DOB: MM/DD/YYYY

| DATE | FACILITY/ PROVIDER | MEDICAL EVENTS | BATES REF |
|------------|-----------------------|---|-----------------------------|
| | | expected range for age. The infant had a normal temperature and tone started to increase around this time and the cry more vigorous. Heart rate normal and lungs sounds coarse but equal bilaterally. Examination otherwise normal. This child will need ongoing post resuscitative care. Hand off provided verbally to Dr. Benbow. Infant was born at 0754 hours. | |
| 12/23/YYYY | Provider/ Hospital | @0839 hours: History and Physical: Admitted from: Birthing room. Current medications: Erythromycin ointment 0.5% Hepatitis B pediatric vaccine 10 mcg/0.5 ml Phytonadione 1 mg 0.5 ml inj Zinc oxide topical ointment Maternal Labor Onset Methods: Spontaneous, Augmented Delivery Type, Birth: C-Section Reason for C-section: Lack of descent of fetal head Delivery Nuchal Cord Times: None Date, Time of Birth: 12/23/17, 0754 hours Maternal ROM to Delivery Hr Calc: 7.33 hr Maternal Amniotic Fluid Color: Clear Newborn Delivery Info: Resuscitation at Birth: CPAP, Laryngoscopy, Oxygen, Positive pressure ventilation, Pulse oximeter, Suction Apgar 1 Minute: 1 Apgar 5 Minute: 6 Apgar 10 Minute: 9 Vitals: Pulse 176, resp. rate 40, temp 95 Physical examination: General: No acute distress, Responsive, Under radiant warmer. Eye: Normal conjunctiva. Pupil: Equal. HENT: Normocephalic, Nares patent, Anterior fontanelle open/soft/flat, Ears normally set and rotated, Palate intact. Neck: Supple, Full range of motion, Clavicles intact. Respiratory: Breath sounds are equal, Course breath sounds bilaterally. No retractions. Cardiovascular: Normal rate, Regular rhythm, No murmur, Normal peripheral perfusion. Gastrointestinal: Soft, Non-distended, Normal bowel sounds, 3 vessel umbilical cord, Anus patent. Genitourinary: Normal genitalia for age and sex, No lesions. Musculoskeletal: Normal range of motion, No deformity, No hip clicks. Integumentary: Warm, Dry, Pink. | Ex 2 000912- Ex 2 000917 |

Patient 1
Patient 2

DOB: MM/DD/YYYY
DOB: MM/DD/YYYY

| DATE | FACILITY/ PROVIDER | MEDICAL EVENTS | BATES REF |
|------------|-----------------------|--|-----------------------------|
| | | <p>Neurologic: Alert, Moves all extremities appropriately, Moro, rooting, sucking reflexes are normal, No focal deficits, Hand grasp present, Toe grasp present.</p> <p>Medication Administered: Phytonadione, and Erythromycin 0.5% ophthalmic ointment applied in both eyes.</p> <p>Impression and Plan: Diagnosis Status post delivery at term. Term female infant born via primary C-section due to failure to descend. GBS positive, received greater than 4 hours of antibiotics.</p> <p>Condition: Stable.</p> <p>Plan: Breast feeding on demand. Formula feeding: Infant required resuscitation including CPR and PPV. Improved and on room air following resuscitation with normal blood sugars. Monitor respiratory status and vitals closely. GBS positive with adequate antibiotics.</p> | |
| 12/23/YYYY | Provider/ Hospital | <p>@0905 hours: Nursing assessment:</p> <p>Level of consciousness: Alert, active with stimulation Muscle tone: Normal Respiratory effort: Easy, regular Skin: Normal for ethnicity, pink, acrocyanosis Vitals: Pulse 136, resp. rate 60, temp 97.8, SpO2 99%</p> | Ex 2 001013 |
| 12/23/YYYY | Provider/ Hospital | <p>@0920 hours: Blood gas:</p> <p>pH 7.13, pCO2 54, pO2 15, O2 sat 12, base excess -12 bicarbonate 18.2</p> | Ex 1 000082- Ex 1 000083 |
| 12/23/YYYY | Provider/ Hospital | <p>@1000 hours: Nursing assessment:</p> <p>Vitals: Pulse 148, resp. rate 56, temp 98.4, SpO2 99%</p> | Ex 2 001012 |
| 12/23/YYYY | Provider/ Hospital | <p>Nursing notes:</p> <p>@1745 hours: Mother of baby called out through call light- mother reports baby is purple; C Roberts, RN to bedside- infant dusky, limp, and unresponsive; C Roberts, RN took baby from father's arms, placed in crib, and stimulated the baby while transporting baby to nursery. @1747 hours: Infant in nursery, pulse ox connected - oxygen saturation 100% @1801 hours: Infant cyanotic with apneic episode</p> | Ex 2 001045- Ex 2 001046 |
| 12/23/YYYY | Provider/ Hospital | <p>@1800 hours: X-ray of chest:</p> <p>Clinical History: Respiratory distress.</p> | Ex 2 000921- Ex 2 000922 |

| DATE | FACILITY/ PROVIDER | MEDICAL EVENTS | BATES REF |
|------------|-----------------------|---|-----------------------------|
| | | Impression: No active cardiopulmonary disease. | |
| 12/23/YYYY | Provider/ Hospital | Nursing notes: @1802 hours: Infant brought to nursery by C. Roberts, RN. Infant pale, O2 sat at 68% via right wrist. Infant to warming table. @1803 hours: Dr. Benbow notified of low temp and low sat. Will continue to monitor and Dr is coming in to see patient. @1808 hours: Noted infant with intermittent apneic spells after desaturation. Gave PPV. @1809 hours: Father of infant at bedside. X-ray and lab at bedside. @1820 hours: Noted infant's O2 sat drops spontaneously down to 70's. Apneic episodes noted gave PPV times 30 sec. | Ex 2 001045 |
| 12/23/YYYY | Provider/ Hospital | @1822 hours: Lab report: High: Nucleated RBC 11, monocyte 13% | Ex 2 000935- Ex 2 000936 |
| 12/23/YYYY | Provider/ Hospital | Nursing notes: @1825 hours: Dr. Benbow to call NICU @1827 hours: Dr. Benbow on phone with NICU @1845 hours: PPV for 15 seconds @1846 hours: Respiratory therapist at cribside – respiratory to take over PPV @1851 hours: Dr. Benbow attempting to intubate – unsuccessful – return to CPAP @1854 hours: Dr. Benbow attempting to intubate – CO2 detector negative – tube removed - return to CPAP @1915 hours: Dr from ER at cribside to attempt intubation @1930 hours: Dr. Snider at bedside – intubation successful with a 3.0 @1940 hours: X-ray here to check for tube placement | Ex 2 001044- Ex 2 001045 |
| 12/23/YYYY | Provider/ Hospital | @1944 hours: Progress notes: Called by Dr. Benbow, baby in respiratory distress which is worsening awaiting arrival of NICU transport team. Intubated with Miller 0 3.0 ETT, stylet without problem. BBS equal, color change on CO2 check, chest X-ray pending. Then placed 24 g in left saphenous vein. Patient stable sats 94% on O2. Plan remains transfer to NICU in Springfield. | Ex 2 000890 |
| 12/23/YYYY | Provider/ Hospital | Nursing notes: @1950 hours: Respiratory continues to provide PPV | Ex 2 001044 |
| 12/23/YYYY | Provider/ Hospital | @1958 hours: NICU Transfer summary: At approx 1800 hours, I was called to the bedside of a then 10 hour old female infant who received resuscitation including CPR and PPV following pLTCS for failure to descend. She was able to be weaned to room air following resuscitation and did well throughout the day. At 1800 hours, the nurse was called to the patients room due to parents reports she went limp, turned purple and became unresponsive. After sternal rub she | Ex 2 000907- Ex 2 000911 |

| DATE | FACILITY/ PROVIDER | MEDICAL EVENTS | BATES REF |
|------------|-----------------------|--|-------------|
| | | <p>became alert and began breathing again. She then continued to desat into the 70s until stimulated and her pulse ox was noted to go up to 80-90s. She was taken back to the nursery for further management. She was started on PPV with CPAP and would have episodes of apnea in which she would again desaturated. Due to continued desaturations and worsening into the 50s, intubation was attempted and successful after several attempts and consulting anesthesia. The NICU was consulted for transfer and further management instructions.</p> <p>Vitals: Pulse 142, temp 95, resp. rate 60, SpO2 83%, O2 delivery by mask CPAP, O2 flow 10</p> <p>Physical examination: General: No acute distress, Responsive. Respiratory: Breath sounds are equal. Pattern: Apneic episodes. Breath sounds: Bilateral. Cardiovascular: Normal rate, Regular rhythm, No murmur, Normal peripheral perfusion. Gastrointestinal: Soft, Normal bowel sounds, No organomegaly. Musculoskeletal: Normal range of motion, No swelling, No deformity. Integumentary: Warm, Dry, Pink. Neurologic: Alert, Noted to have occasional jerking movements of the hands at the wrist.</p> <p>Labs: WBC 19.5, hemoglobin 17.4, hematocrit 51.3, platelet 256, blood glucose 82</p> <p>Condition: Fair.</p> <p>Medication Administered: No Hepatitis B vaccine, Phytonadione, and erythromycin 0.5% ophthalmic ointment applied in both eyes.</p> <p>Impression and Plan Diagnosis: Acute respiratory failure with hypoxia. Newborn.</p> <p>Course: Worsening. Orders: Consult with NICU. Given orders to start IV D10 W at 80 ml/kg/day. Ampicillin 100 mg/kg and Gentamicin 4 mg/kg. Additional fluid bolus of normal saline 30 ml given over 30 minutes. Blood gas was obtained. CBC and CRP done. Blood culture pending. X-ray done with limited septic work up was normal. X-ray for tube placement pending.</p> <p>Disposition: Transfer to other facility: NICU for higher level of care.</p> | |
| 12/23/YYYY | Provider/ Hospital | Nursing notes: | Ex 2 001044 |

Patient 1
Patient 2

DOB: MM/DD/YYYY
DOB: MM/DD/YYYY

| DATE | FACILITY/ PROVIDER | MEDICAL EVENTS | BATES REF |
|------------|-----------------------|---|-----------------------------|
| | | @2010 hours: Transport team here. Report given. Dr. Benbow remains in nursery. Care assumed by transport team. | |
| 12/23/YYYY | Provider/ Hospital | @2035 hours: Lab report: High: Glucose 129 | Ex 2 000937 |
| 12/23/YYYY | Provider/ Hospital | @2043 hours: X-ray of chest: Reason for exam: Intubation Impression: 1. New finding left perihilar infiltrate. 2. Patient intubated. 3. Right side is unremarkable. Normal inflation. | Ex 2 001061 |
| 12/23/YYYY | Provider/ Hospital | @2045 hours: Blood gas: pH 7.23, pO2 47, pCO2 37, O2 sat 76, base excess -11, HCO3 15.5 | Ex 2 000938- Ex 2 000939 |
| 12/23/YYYY | Provider/ Hospital | @2114 hours: Transfer Report: Transport from: Cox Branson Transport to: Mercy NICU Reason for transfer: Higher level of care Physical condition: Newborn, intubated. Intubated with ETT 3.0 Risk of transfer: Desaturation Mode of transportation and acuity: ALS ambulance, emergent | Ex 2 000925- Ex 2 000938 |
| 12/23/YYYY | Provider/ Hospital | Nursing notes: @2117 hours: Infant in transport isolette and taken to mom's room before departing unit. Transported to Mercy. | Ex 2 001044 |
| 12/23/YYYY | Provider/ Hospital | EMS report: (Poorly scanned pages) Primary impression: Respiratory failure Secondary complaint: Meconium aspiration Transfer reason: Physician order, higher level of care Called to transport 39 week term infant from Cox Branson to Mercy Springfield NICU. Sending physician: Benbow Receiving physician: Vish Patient transport details: How was patient moved to ambulance: Stretcher Patient position during transport: Supine How was patient moved to ambulance: Stretcher | Ex 9 001306- Ex 9 001310 |

Patient 1
Patient 2

DOB: MM/DD/YYYY
DOB: MM/DD/YYYY

| DATE | FACILITY/ PROVIDER | MEDICAL EVENTS | BATES REF |
|--|-----------------------|---|-------------|
| | | <p>Neurological: Noticed rhythmic jerking movement during assessment, physician notified and Phenobarbital given</p> <p>Call received: 1829 hours Dispatched: 1900 hours Enroute: 1923 hours On scene: 2005 hours At patient: 2012 hours Depart scene: 2126 hours At destination: 2210 hours Patient transferred: 2224 hours</p> <p>Narrative: Called to transport 39 week term infant from Cox Branson to Mercy Springfield NICU. Air transport unavailable. Ground transport arranged. Patient was born earlier today by C-section for failure to descend, thick meconium was present at delivery and CPR was given. Patient was intubated for meconium aspiration briefly and suctioned below the cord and meconium was pulled out. Per Cox, patient recovered and was on room air most of the day. Around 1800 hours, the patient was feeding with parents when infant went cyanotic. Patient was taken nursery and given positive pressure ventilation. Patient is now requiring constant stimulation to breathe and remains on PPV using CPAP with FiO2 60%. No significant maternal history reported at this time.</p> <p>Upon arrival patient is under radiant warmer being ventilated with neopuff by hospital RT per ETT. Patient is limp/hypotonic, eyes are open and looking around. Assessment completed and X-ray looked at, ETT tube pulled back 2 cm to 9 cm at the gum. OG inserted and air pulled off belly, OG left open to air for transport. IV has been started PTA in right foot with 24 gauge. D10W going at 80 ml/kg/day. Ampicillin given PTA. Rhythmic jerking of extremities noticed during assessment. All findings and vitals reported to Dr. Vish. Orders received for vent, meds and fluids. Consents and plan of care discussed with and signed by mother/family. Patient secured in Isolette. Isolette secured in ambulance. Patient tolerated transport well. Patient has had increasing oxygen needs. Patient was originally started on an FiO2 of 60% and has need to increase to max of 99% FiO2. Breath sounds have remained clear throughout transport. SBAR and patient care handled off to Robin RN.</p> | |
| 12/23/YYYY | Provider/ Hospital | <p>Other related records:</p> <p>Assessment, medication sheets, intake/output record</p> <p>Bates Ref: Ex 2 000887, Ex 2 000889, Ex 2 000929- Ex 2 000930, Ex 2 000933- Ex 2 000934, Ex 2 000943- Ex 2 001060</p> | |
| AB Hospital Springfield (12/23/YYYY – 01/09/YYYY) NICU management | | | |
| 12/23/YYYY | Provider/ | @2300 hours: Procedure Report: | Ex 9 000013 |

Patient 1
Patient 2

DOB: MM/DD/YYYY
DOB: MM/DD/YYYY

| DATE | FACILITY/ PROVIDER | MEDICAL EVENTS | BATES REF |
|------------|-----------------------|--|-----------------------------|
| | Hospital | <p>Oral intubation performed per protocol with a 3.5 mm endotracheal tube. Vocal cords located with 0 blade and laryngoscope. Tip of endotracheal tube visualized passing through the vocal cords. Upon ambu, immediate condensation vapor present within tube as well as increase in infants oxygen saturations. Bilateral breath sounds auscultated equally at midaxillary line. CO2 indicator had appropriate color change.</p> <p>Endotracheal tube secured midline to upper lip with Benzoin, elastoplast base piece, and Elastoplast stabilization piece. Tube is 9 cm at the gum. Infant to conventional ventilator with documented settings. Tube placement confirmed per X-ray with tip at T2, confirmed with Ashley Chapman NNP.</p> | |
| 12/23/YYYY | Provider/ Hospital | <p>@2332 hours: X-ray of chest:</p> <p>The tip of the ET tube lies in the upper thoracic trachea. An OG tube is directed into the stomach. The pelvis is excluded from the examination. A probable umbilical vein catheter overlies the midline abdomen with its distal portion looped back upon itself over the right, upper quadrant. A portion of the second catheter is noted looped over the lower midline abdomen.</p> <p>The lungs are clear. The cardiophymic silhouette is normal. The bowel gas pattern is nonspecific.</p> | Ex 9 000394 |
| 12/23/YYYY | Provider/ Hospital | <p>@2358 hours: X-ray of chest:</p> <p>Reason for exam: Line placement</p> <p>Findings: ETT terminates above the carina. Enteric tube terminates in the stomach. UVC terminates near the T3 level. UVC terminates near the junction of the right atrium and SVC. There is no lung consolidation, pleural effusion, or pueumothorax. The bowel gas pattern is unremarkable.</p> | Ex 9 000398- Ex 9 000399 |
| 12/24/YYYY | Provider/ Hospital | <p>@0017 hours: Procedure Report:</p> <p>Insert Umbilical Venous Cath:</p> <p>The infant was/secured supine in a developmentally supportive position. The umbilicus and abdomen were prepped with betadine and draped with sterile towels to cover infant. Umbilical tape was placed around the base of the umbilicus and the cord was cut 1 cm from the skin. A 5 French Argyle line was placed in the umbilical vein and advanced to the 8 cm. Free flow of blood was obtained. Radiologic confirmation of the catheter is T9. The catheter was secured to the abdomen with a piece of transparent dressing. The infant tolerated the procedure well. Confirmed with Ashley Chapman NNP</p> <p>Insert Umbilical Arterial Cath:</p> <p>The infant was/secured supine in a developmentally supportive position. The umbilicus and abdomen were prepped with betadine and draped with sterile towels to cover infant. Umbilical tape was placed around the base of the umbilicus and the cord was cut 1 cm from the skin. A 5 French</p> | Ex 9 000014 |

| DATE | FACILITY/ PROVIDER | MEDICAL EVENTS | BATES REF |
|------------|-----------------------|--|-----------------------------|
| | | Argyle line was placed in the umbilical artery and advanced to the 17 cm. Free flow of blood was obtained. Radiologic confirmation of the catheter is T8. The catheter was secured to the abdomen with a piece of transparent dressing. The infant tolerated the procedure well. Confirmed with Ashley Chapman NNP. The central line checklist was followed. | |
| 12/24/YYYY | Provider/ Hospital | <p>@0531 hours: X-ray of chest:</p> <p>Findings: Comparison dated 12/23/YYYY at 2337 hours. The umbilical artery catheter tip is been retracted to the T7-8 level. The umbilical vein catheter has been retracted to T9 level. The tip of the tube remains in the mid thoracic trachea. The OG tube tip remain within the stomach. The lungs are clear. The cardiothymic silhouette is normal. The bowel gas pattern is nonspecific.</p> | Ex 9 000395- Ex 9 000396 |
| 12/24/YYYY | Provider/ Hospital | <p>@0742 hours: Pharmacy Consultation:</p> <p>Current Antibiotic Therapies: Gentamicin and Ampicillin Day# 1 of therapy</p> <p>Assessment: Baby is a 1 days female who is currently receiving Gentamicin 12.5 mg (approx. 4 mg/kg 3.14 kg) IV every 24 hours and Ampicillin 314.1 mg IV every 8 hours for rule out sepsis. WBC 16.9 K/uL today. Patient Tmax 99.4 °F. Renal function: SCr 0.94 mg/dl today, not enough data to assess average urine output at this time.</p> <p>Plan: Continue Gentamicin 12.5 mg (approx. 4 mg/kg) IV every 24 hours. At this time will not obtain levels. If therapy will go > 72 hours or renal function/clinical status changes, will need to obtain Gentamicin levels with a goal peak of 7-10 mcg/ml and trough< 1.2 mcg/ml. Pharmacy will continue to monitor the patient's labs and renal function daily.</p> <p>Pharmacy will continue to monitor the patient's labs. We will follow-up with daily progress note for Vancomycin and Aminoglycoside Consults and will write a progress note in the future if any additional dosage adjustment is needed on other renal consults.</p> | Ex 9 000015- Ex 9 000016 |
| 12/24/YYYY | Provider/ Hospital | <p>@0920 hours: Ultrasound of head:</p> <p>Indication: Clinical seizures</p> <p>Reason for exam: Premature birth</p> <p>Findings: The ventricles are of normal size and configuration. There are no hemorrhage. There is no evidence of traumatic hemorrhage or intraventricular hemorrhage. There is an 8 mm diameter cystic appearing structure just caudad of the splenium of the corpus callosum. This could potentially represent a small pineal cyst</p> | Ex 9 000396- Ex 9 000397 |
| 12/24/YYYY | Provider/ | @0924 hours: Echocardiogram: | Ex 9 000244- |

Patient 1
Patient 2

DOB: MM/DD/YYYY
DOB: MM/DD/YYYY

| DATE | FACILITY/ PROVIDER | MEDICAL EVENTS | BATES REF |
|------------|-----------------------|---|-----------------------------|
| | Hospital | <p>Indications and history: Rule out PPHN</p> <p>Summary and Conclusion:</p> <ul style="list-style-type: none">- Left ventricle: The cavity size was normal. Systolic function was normal.- Right ventricle: The cavity size was normal. Systolic function was normal. The estimated peak pressure was 12 mmHg to 18 mmHg.- Ventricular septum: There was a congenital defect in the apical septum- Aortic arch: The aortic arch was normal without evidence of coarctation. <p>Impressions: Small muscular VSD, no evidence of pulmonary hypertension. Recommend follow up for VSD at age 2-3 months.</p> | Ex 9 000248 |
| 12/24/YYYY | Provider/ Hospital | <p>@1305 hours: History and Physical:</p> <p>Admit type: Acute transfer</p> <p>Transfer Comment: Call received from Dr. Benbow regarding a six hour old term infant who turned dusky and is having repeated periods of desaturation necessitating NCPAP, 60% Oxygen and stimulation. History at birth suggestive of poor transition necessitating CPR for approx. 3 minutes with Perinatal Meconium exposure.</p> <p>Asked Dr. Benbow to continue respiratory support, get chest X-ray read by radiologist and call me with blood gas. IVF, IDS and antibiotics initiated. Blood gas showed base deficit 11 and HCO3 15.5. Normal saline bolus given. Subsequently the infant was intubated and ventilated for ongoing desaturation episodes by Anesthesiologist with 3 mm ETT. Mercy Transport team arrived, readjusted ET Tube, stabilized infant. They noted involuntary movements. I asked them to load baby with Phenobarbital 20 mg/kg one time and then infant was brought back by land. On arrival infant stable. ETT changed to 3.5 mm, umbilical lines placed. Chest X-ray consistent with meconium aspiration. Involuntary movement again noted. HSV surface swabs sent. Keppra commenced.</p> <p>Maternal history: Medications during pregnancy or labor: Morphine Pepcid Ancef Penicillin - Multiple doses > 4 hours prior to delivery Azithromycin x1 Bicitra Fentanyl Penicillin Zofran Prenatal vitamins</p> <p>Pregnancy Comment: Denies the use of drugs, alcohol, or tobacco.</p> | Ex 9 000017- Ex 9 000024 |

Patient 1
Patient 2

DOB: MM/DD/YYYY
DOB: MM/DD/YYYY

| DATE | FACILITY/ PROVIDER | MEDICAL EVENTS | BATES REF |
|------|-----------------------|--|-----------|
| | | <p>GC/Chlamydia negative, Hep C negative. No recent infections.</p> <p>Procedures/Medications at Delivery: NP/OP Suctioning, Warming/Drying, Monitoring VS, Supplemental O2, Positive pressure ventilation, intubation, cardiac compression. APGARS 1 min - 1, 5 min – 6, 10 min – 9</p> <p>Labor and Delivery Comment: CS for failure to descend. Fluid had been clear prior to delivery but was thick meconium at delivery. Intubated and suctioned below the cords and green meconium obtained. Required CPR/PPV for 30 seconds. Infant stable after delivery - went to mother's room. At approximately 6 hours of age, infant non-responsive with a fixed stare in the parents room. Brought to the nursery and continued to have desats requiring bagging. Transported initiated.</p> <p>Admission Comment: NPO PIV with D10 running at FG 80. On Amp and Gent. CBC and blood culture drawn in Branson. Ventilated in Branson. Placed on conventional ventilation on arrival to Mercy. Seizure activity noted by the transport team - Phenobarb given x1. Continued having rhythmic jerking on arrival - Kepra initiated. UAC and UVC placed. HUS ordered.</p> <p>Admission physical exam: Vitals: Pulse 159, resp. rate 51, BP 67/29, SpO2 97%</p> <p>Intensive cardiac and respiratory monitoring, continuous and/or frequent vital sign monitoring. Bed Type: Radiant Warmer General: The infant is hyperactive. Variable tone and activity. Perfusion OK. Head/Neck: Anterior fontanelle is soft and flat. No oral lesions. Bilateral red reflex noted. Chest: There are increased adventitial breath sounds (rales and rhonchi) heard over all lung fields. Breath sounds are equal bilaterally Heart: Regular rate and rhythm, without murmur. Pulses are normal. Abdomen: Soft and flat. No hepatosplenomegaly. Normal bowel sounds. Three vessel umbilical cord. Hernia orifices free. Genitalia: Normal external genitalia are present. Female. Extremities: No deformities noted. Normal range of motion for all extremities. Hips show no evidence of instability. Neurologic: Variable tone and activity Skin: The skin is pink and well perfused. No rashes, vesicles, or other lesions are noted. Caput with bruising.</p> <p>Active medications: Ampicillin Gentamicin</p> | |

Patient 1
Patient 2

DOB: MM/DD/YYYY
DOB: MM/DD/YYYY

| DATE | FACILITY/ PROVIDER | MEDICAL EVENTS | BATES REF |
|------|-----------------------|---|-----------|
| | | <p>Phenobarbital Normal saline Calcium gluconate Curosurf Levetiracetam Lorazepam</p> <p>Ventilator setting: SMV, FiO2 0.6, rate 30, PIP 22, PEEP 5, PS 8</p> <p>Nutrition support: Glucoses stable. Infant initially in mother's room and feeding well then brought to nursery at approx. 6 hours of age NPO PIV with D10 to run at FG 80. UAC and UVC placed. Changed to starter TPN at FG 80. 1 /2 NS with Heparin to run to UAC. Plan: Follow</p> <p>At risk for Hyperbilirubinemia History: Infant B+, coombs positive. Antibody screen negative. Plan: Follow</p> <p>Respiratory Diagnosis: Respiratory Insufficiency - onset <= 28 days Meconium Aspiration Syndrome History: Infant initially placed on CPAP at 60% in Branson and continued having events requiring stimulation and bagging. Ventilated by the referral hospital with a 3.0 ETT. Upon arrival of the transport team, infant was not doing well ETT noted to be right mainstem - pulled back and responded well. Transported on the ventilator at -90% O2. Upon arrival to Mercy, infant was placed on conventional ventilator. He was reintubated with a 3.5 ETT without difficulty. O2 weaned considerably after arrival. UAC was placed. Initial ABG => 7.55/21/154/-4/18/100 on 35% O2. Plan: 12/23/YYYY: One dose surfactant given. Watch out for Pulmonary Hypertension. Plan CECHO tomorrow AM. Then wean as tolerated.</p> <p>Cardiovascular: Hypoperfusion < 28 days Comment: Rx Normal saline bolus History: In referral hospital, Acidosis and poor perfusion. Normal saline bolus given with improvement. On admit here, HD stable on admission. Plan: Monitor</p> <p>Sepsis-newborn-suspected Diagnosis: Sepsis-newborn-suspected</p> | |

| DATE | FACILITY/ PROVIDER | MEDICAL EVENTS | BATES REF |
|------------|-----------------------|---|-----------------------------|
| | | <p>History: Maternal GBS positive. Multiple doses of Ancef > 4 hours prior to delivery. CBC, blood culture, and CRP drawn in Branson. Amp and Gent initiated. HSV swabs ordered for 24 and 72 hours due to rhythmic jerking - no documented maternal history. CRP 0.147.</p> <p>Plan: 12/23/YYYY: Blood culture, ET Aspirate pending. Chest X-ray: Consistent with Meconium aspiration. Plan minimum 7 days antibiotics. Will need LP prior to discontinuation of antibiotics.</p> <p>Hematology History: CBC at Branson => WBC 19.5, Hct 51.3, Platelet 256k, and 1% band. Plan Follow every morning.</p> <p>Neurology: Diagnosis: Perinatal depression Neuroimaging: Cranial ultrasound – small pineal cyst a possible Other: EEG History: Transport team noted rhythmic jerking of extremities - one dose of Phenobarb given. Variable tone on admission. Occasionally hypotonic, then irritable. Initially planned to watch to see if recurs, however infant continued to have tonic clonic movements of all extremities, especially the hands. Keppra initiated and HUS ordered for 12/24. Lactic acid drawn on admission gas=> 7.68.</p> <p>Assessment Admission Assessment: Poor transition at birth. Resuscitation included CPR as per referral physician Dr. Benbow MD Cord pH: 7.06. Initial Blood Gas: HCO3 15.5, Base deficit 11 as per GAS drawn in referral hospital. Involuntary movements noted at about 9 hours of age. Acidosis corrected with Normal saline bolus. Not a candidate for Therapeutic Hypothermia as per Classical indications. (Vish) Plan: Follow.</p> <p>Parental support: Plan: Parental support and social work input as needed.</p> <p>Term infant: Comment: GA: 39 6/7 weeks BW: 3090g History: Infant is AGA.</p> <p>Hearing screen: ABR</p> <p>Immunization: Hepatitis B</p> | |
| 12/24/YYYY | Provider/ Hospital | @1649 hours: EEG report: | Ex 9 000024- Ex 9 000025 |

| DATE | FACILITY/ PROVIDER | MEDICAL EVENTS | BATES REF |
|------------|-----------------------|--|-----------------------------|
| | | <p>Reason for EEG: Involuntary movements in a newborn for evaluation of seizures.</p> <p>This is a 10-20 international electrode system Neonatal scalp electrode placement EEG performed on a day old newborn born at term with fetal decelerations, required CPR for 3 min but at 9 hours of life developed dusky spells with desaturation and noted involuntary rhythmic jerky movements.</p> <p>Medications: Received Phenobarbital and Keppra</p> <p>EEG background is discontinuous with diffusely attenuated background with variability with intermittent synchronous bursts of variable amplitude delta mixed with polyfrequency waves. No sleep -wake cycle differentiation appreciated. There were subclinical left temporal and right temporal independent electrographic seizure activity noted lasting for 1 min and 30 seconds respectively followed by voltage suppression diffusely after the event lasting for 1-1.30 min.</p> <p>A clinical event marked at 1447 with Left upper extremity rhythmic jerking coincided with right temporal 1 Hz spike and slow wave rhythmic activity for 20 seconds.</p> <p>EKG monitoring with single lead EKG shows sinus rhythm.</p> <p>EEG interpretation: This is an abnormal EEG with diffuse voltage attenuation suggestive of neonatal encephalopathy. There are focal onset epileptiform seizures noted in both temporal lobes individually suggestive of bilateral onset focal seizures. This can be seen in hypoxic ischemic injury, infectious, genetic or metabolic etiologies. Clinical correlation is suggested.</p> | |
| 12/24/YYYY | Provider/ Hospital | <p>@1930 hours: Progress Notes:</p> <p>Current: Intubated on SIMV NPO/TPN/IL FG keeping at 80. UAC/UVC On Antibiotics HUS shows possible pineal cyst EEG positive for seizures. Was loaded on Keppra and started on maintenace. If needed will introduce Phenobarbital as well. MRI on day 8-10. Echo shows small muscular VSD, no evidence of pulmonary hypertension. Recommend follow up for VSD at age 2-3 months.</p> <p>Physical examination: Head/Neck: Anterior fontanelle is soft and flat. No oral lesions. Chest: Breath sounds are equal bilaterally. Neurologic: Slightly hypotonic. Reacts to touch with lower limb movements, not so much upper limb movements. No exaggerated jerks.</p> | Ex 9 000026- Ex 9 000030 |

Patient 1
Patient 2

DOB: MM/DD/YYYY
DOB: MM/DD/YYYY

| DATE | FACILITY/ PROVIDER | MEDICAL EVENTS | BATES REF |
|------------|-----------------------|--|-----------------------------|
| | | <p>Skin: The skin is pink and well perfused. No rashes, vesicles, or other lesions are noted. Caput with bruising.</p> <p>Respiratory: 12/24/YYYY: Stable on SIMV. Low settings but FiO2 50%</p> <p>Cardiovascular: Plan 12/24/YYYY: Stable BP, Perfusion and UOP. Small muscular VSD, no evidence of pulmonary HTN. Recommend follow up for VSD at age 2-3 months.</p> <p>Sepsis newborn – suspected: Amp and Gent initiated. HSV swabs ordered for 24 and 72 hours due to rhythmic jerking - no documented maternal history</p> <p>Hematology: Plan: 12/24/YYYY: WCC 16.9, hematocrit 48.4, platelet 268, Neutrophils 89, Bands 3, Lymphocytes 7.</p> <p>Neurology: Plan: 12/24/YYYY: Slightly diminished tone, upper limb more diminished. Noted for seizures in EEG. Was already loaded with Keppra. Dosing changed to 20 mg/kg every 8 hours. Started 24 hrs EEG. If needed will introduce Phenobarbital as well. MRI on day 8-10.</p> | |
| 12/24/YYYY | Provider/ Hospital | <p>@ 2223 hours: X-ray of chest:</p> <p>Indication: Increasing FiO2 needs</p> <p>Findings: Comparison dated 12/24/YYYY at 0458 hours. Has been interval development of some focal atelectasis in the upper lobe of the right lung. The left lung is hyperinflated. The tip of the ET tube lies the lower thoracic trachea. The OG tube and umbilical catheters are stable.</p> | Ex 9 000400- Ex 9 000401 |
| 12/25/YYYY | Provider/ Hospital | <p>Discharge Summary:</p> <p>Patient presented in active labor and admitted. She was augmented with Pitocin. SROM at complete. She received adequate antibiotics for GBS prophylaxis. She made progress with pushing from 0 to +1 station but then had arrest of descent despite adequate contractions, SROM and pushing with epidural turned off and was taken back for a non scheduled C-section. Her C-section was uncomplicated. Her postpartum course was normal. Her infant did get sent to NICU for respiratory distress. Patient doing well postpartum. Denies chest pain, shortness of breath, or calf pain. Reports decreasing lochia. Urinating without difficulty. Pain well controlled on oral pain medications. She is pumping a small amount of colostrum.</p> | Ex 1 000032- Ex 1 000034 |

Patient 1
Patient 2

DOB: MM/DD/YYYY
DOB: MM/DD/YYYY

| DATE | FACILITY/ PROVIDER | MEDICAL EVENTS | BATES REF |
|-------------------------------|-----------------------|---|-----------------------------|
| | | <p>Admitting Diagnosis: Term pregnancy.</p> <p>Discharge Diagnosis: Postpartum examination following cesarean delivery.</p> <p>Prescription: Ibuprofen 800 mg Oxycodone 5 mg</p> <p>Discharge Status: Stable. Discharge disposition: Discharge to home self care.</p> <p>Orders: Ok to discharge to home. Given discharge instructions. Follow up in clinic next week. Call sooner with any concerns.</p> | |
| 12/22/YYYY - 12/25/YYYY | Provider/ Hospital | <p>Other related records:</p> <p>Assessment, flow sheets, medication sheets, orders, patient education, plan of care, Input / Output Record, Medication Reconciliation Record</p> <p>Bates Ref: Ex 1 000001, Ex 1 000041- Ex 1 000046, Ex 1 000073- Ex 1 000079, Ex 1 000049- Ex 1 000060, Ex 1 000084- Ex 1 000429, Ex 1 000475- Ex 1 000542, Ex 1 000017, Ex 3 000472- Ex 3 000488, Ex 9 000034- Ex 9 000035</p> | |
| 12/25/YYYY | Provider/ Hospital | <p>@0440 hours: X-ray of chest:</p> <p>Findings: There has been an interval further increase in atelectasis in the right lobe right lung. Left lung is clear.</p> <p>The ET tube and NG tube are stable. The umbilical artery and vein catheters appear stable. The bowel gas pattern is non-specific.</p> | Ex 9 000399- Ex 9 000400 |
| 12/25/YYYY | Provider/ Hospital | <p>@0757 hours: Pharmacy Progress Notes:</p> <p>Assessment: Patient is a 2 days female who is currently receiving Gentamicin 12.5 mg (approx. 4 mg/kg 3.14 kg) IV every 24 hours and Ampicillin 314.1 mg IV every 8 hours for rule out sepsis. WBC 13.9 K/uL today. Patient Tmax 99.2 °F. Renal function: SCr 0.48 mg/dl today, and average urine output yesterday was 3.4 ml/kg/hr.</p> <p>Plan: Continue Gentamicin 12.5 mg (approx. 4 mg/kg) IV every 24 hours. At this time will not obtain levels. If therapy will go > 72 hours or renal function/clinical status changes will need to obtain Gentamicin levels with a goal peak of 7-10 mcg/ml and trough < 1.2 mcg/ml. Pharmacy will continue to monitor the patient's labs and renal function daily.</p> <p>Pharmacy will continue to monitor the patient's labs. We will follow-up with daily progress note for Vancomycin and Aminoglycoside Consults and will write a progress note in the future if any additional dosage adjustment is needed on other renal consults.</p> | Ex 9 000030- Ex 9 000032 |

Patient 1
Patient 2

DOB: MM/DD/YYYY
DOB: MM/DD/YYYY

| DATE | FACILITY/ PROVIDER | MEDICAL EVENTS | BATES REF |
|------------|-----------------------|---|-----------------------------|
| 12/25/YYYY | Provider/ Hospital | @0900 hours: Procedure report: 1.9 Fr argon PICC placed in right basilic using sterile technique. Radiologic confirmation per Dr. Arnab. Catheter tip in the Pre SVC. 13 cm catheter inserted, 0 cm external. Secured with sterile transparent dressing. | Ex 9 000032 |
| 12/25/YYYY | Provider/ Hospital | @0922 hours: X-ray of chest: Findings: There is persistent atelectasis involving the upper lobe of the right lung. The tip of the ET tube lies in the upper thoracic trachea. The OG tube remains in stable position. A PICC is been placed on the right. A lead or other linear radiodensity overlies the right axilla and the upper right chest. The tip of the umbilical artery and vein catheters are stable. | Ex 9 000404- Ex 9 000405 |
| 12/25/YYYY | Provider/ Hospital | @0948 hours: X-ray of chest: Reason for exam: Line placement Findings: Dense consolidation or atelectasis persists in the upper lobe of the right lung. The tip of the right PICC overlies the region of the right subclavian vein. The tip of the ET tube lies the lower cervical trachea. The OG tube tip remains within the stomach. Umbilical vein and artery catheters are stable. | Ex 9 000405- Ex 9 000406 |
| 12/25/YYYY | Provider/ Hospital | @1001 hours: X-ray of chest: Findings: The tip the ET tube lies at the thoracic inlet. The OG tube tip lies within the stomach. The umbilical artery and vein catheters are stable. The tip of the right PICC appears to lie in the region of the confluence of the right internal jugular vein with the right subclavian vein. Dense consolidation or atelectasis is again noted in the upper lobe right lung. The left lung is clear. The cardiothymic silhouette and pulmonary vasculature are normal. | Ex 9 000406- Ex 9 000407 |
| 12/25/YYYY | Provider/ Hospital | @1619 hours: X-ray of chest: Reason for exam: Pneumonia Impression: Improved aeration of the right upper lobe and right mid lung with residual right upper consolidative atelectasis versus airspace disease. Resolution of cardiomeastinal shift from the left to the right is noted when compared to the previous exam. Repositioning of the right upper extremity PICC line now terminating in the SVC. | Ex 9 000408- Ex 9 000410 |
| 12/25/YYYY | Provider/ Hospital | @1800 hours: EEG report: Medications: Phenobarb and Keppra | Ex 9 000033- Ex 9 000034 |

| DATE | FACILITY/ PROVIDER | MEDICAL EVENTS | BATES REF |
|------------|-----------------------|--|--------------|
| | | <p>Background: Background is discontinuous with low voltage and some asynchronous activity consistent with bursts of 1-2 Hz of delta slow waves < 40 uV mixed with theta activity. For major portion of the recording the activity is more depressed over the left frontal area during the asynchrony. There was prolonged periods of depressed background activity with low voltage between these burst activities which improved the next day morning with more background activity with reduced inter burst interval periods from 10-20 sec to 2-4 seconds.</p> <p>Interictal abnormality: There were frequent sharp and poly spike wave abnormalities noted predominantly in right frontal than in right central midline, right temporal and left temporal area. These abnormalities frequency lessened from midnight and by next day noon these noted less frequently in other areas but occasionally noted on right frontal areas still.</p> <p>Ictal abnormality: There were 2 ictal events marked at 1927 and 1934 hr. The clinical activity at 1934 was marked with left upper extremity clonic jerking coincided over right frontal spike and slow wave rhythmic epileptiform activity at 1 Hz frequency spread to right central area also which was electro graphically lasted beyond clinical spell for 1 min 15 seconds.</p> <p>Unmarked clinical RUE jerking noted on vEEG at 1811, 1826 also had similar epiletiform correlate as above.</p> <p>Frequent subclinical electrographic rhythmic epileptiform activity consisting predominantly right frontal and central spike and slow wave complexes lasting for > 10 sec to 2 min were noted at 1803, 1808, 1813, 1817, 1819, 1827, 1818, 1829, 1830, 1841, 1843, 1847, 2137. At 1806 simultaneous left frontal and right frontal variable morphology Spike and slow wave rhythmic activity which spread to both hemispheres during evolution and lasted 1 min longed in the right frontal and central areas compared to left hemisphere and then followed by a depressed undifferentiated background for 1-1.5 min. The subclinical seizure activity lessened after midnight.</p> <p>EKG rhythm: sinus rhythm</p> <p>EEG interpretation: This is an abnormal EEG with predominant right frontal and central focal seizure onset but focal abnormalities also seen from left frontal - temporal onset suggestive of multifocal onset seizures over a depressed and low voltage background activity. The subclinical seizure activity burden reduced from midnight and less frequent to rarely noted today. The background activity showing slight improvement with improved voltage activity with bursts but still has inter burst discontinuity.</p> | |
| 12/25/YYYY | Provider/ | @2059 hours: Progress notes: | Ex 9 000039- |

Patient 1
Patient 2

DOB: MM/DD/YYYY
DOB: MM/DD/YYYY

| DATE | FACILITY/ PROVIDER | MEDICAL EVENTS | BATES REF |
|------|-----------------------|--|-------------|
| | Hospital | <p>Current: Intubated on SIMV NPO/TPN/IL FG keeping at 80. UAC/UVC On Antibiotics</p> <p>Day of life: 2 Today's weight: 3130 gms Change: -10</p> <p>Bed Type: Radiant Warmer General: Pale pink. Icterus+ Sedated. Variable tone and diminished activity Perfusion satisfactory. Head/Neck: Anterior fontanelle is soft and flat. No oral lesions. Neurologic: Slightly hypotonic. Reacts to touch with lower limb movements, not so much upper limb movements. No exaggerated jerks. Skin: The skin is pink and well perfused. No rashes, vesicles, or other lesions are noted. Caput with bruising.</p> <p>Active medications: Ampicillin Gentamicin Calcium gluconate Levetiracetam Lorazepam Acyclovir Phenobarbital</p> <p>Ventilator setting: SMV, FiO2 0.7</p> <p>Nutrition support: NPO/TPN/IL UAC/UVC. FG 80 (Fluid restricted). Noted for high AST, ALT at admission. Consider feeds after 72 hours. CVL for meds. UVC for TPN/SMOF.</p> <p>At risk for Hyperbilirubinemia 12/24/YYYY: Bili 4.3 in AM, 4.9 in PM. Following every 6 hours. 12/25/YYYY: Bili 4.7</p> <p>Respiratory Diagnosis: Respiratory Insufficiency - onset <= 28 days Meconium Aspiration Syndrome Plan: 12/24/YYYY: Stable on SI MV, low settings but FiO2 50% 12/25/YYYY: Increased oxygen due to right lung UZ/MZ atelectasis Nursed left side down and vigorous CPT carried out. PM Chest X-ray shows clearance and infant weaning. Extubate in next 24-48 hrs.</p> | Ex 9 000044 |

| DATE | FACILITY/ PROVIDER | MEDICAL EVENTS | BATES REF |
|------------|-----------------------|---|-----------------------------|
| | | <p>Cardiovascular: Plan: 12/25/YYYY: Stable BP, Perfusion and UOP. CECHO (12/24): Small muscular VSD, no evidence of pulmonary. Recommend follow up for VSD at age 2-3 months.</p> <p>Sepsis-newborn-suspected Plan: 12/25/YYYY: Blood culture, ET Aspirate pending. Chest X-ray: Consistent with Meconium aspiration. Plan minimum 7 days antibiotics. Will need LP prior to discontinuation of antibiotics due to seizure activity.</p> <p>Rule out Herpes - congenital No documented history of herpes. Poor perinatal transition with depression. Refractory seizures by EEG. LFT altered. HSV topical swabs sent on 12/24. Blood PCR for HSV sent on 12/25 and Acyclovir commenced on 12/25. Repeat topical swabs tomorrow AM. Plan: Follow screens. Continue Acyclovir until all HSV culture come back negative. Need LP soon to send for bacterial and HSV screens.</p> <p>Hematology Plan: WCC 13.9, hematocrit 44.1, platelet 256, 1% band</p> <p>Neurology: Diagnosis: Perinatal depression Neuroimaging: Comment: Continuous Video EEG shows ongoing subclinical seizures as per Peds Neuro Thalakoti MD. Phenobarbital dose added overnight. Interpretation at end of 24 hours: EEG interpretation: This is an abnormal EEG with predominant right frontal and central focal seizure onset but focal abnormalities also seen from left frontal - temporal onset suggestive of multifocal onset seizures over a depressed and low voltage background activity. The subclinical seizure activity burden reduced from midnight and less frequent to rarely noted today. The background activity showing slight improvement with improved voltage activity with bursts but still has inter burst discontinuity. Plan: 12/25/YYYY: On Keppra and Phenobarbital. No clinical seizures. 24 hr Video EEG completed. Phenobarb maintenance dose increased. Level on Tuesday morning.</p> | |
| 12/26/YYYY | Provider/ Hospital | <p>@0441 hours: X-ray of chest AP and abdomen:</p> <p>Impression: The tip of the ET tube is above the carina. The tip of the OG tube is over the stomach bubble. The right arm PICC line, the UAC and the UVC are all grossly stable. There is no appreciable pneumothorax. There is mild bilateral predominantly parahilar haze. The right upper lobe is</p> | Ex 9 000402- Ex 9 000403 |

| DATE | FACILITY/ PROVIDER | MEDICAL EVENTS | BATES REF |
|------------|-----------------------|--|-----------------------------|
| | | significantly improved in appearance. The cardiothymic silhouette is unremarkable. The bowel gas pattern is non-specific. | |
| 12/26/YYYY | Provider/ Hospital | <p>@0913 hours: Pharmacy progress notes:</p> <p>Assessment: WBC 14.4. Scr 0.31. Urine output over past 24 hours of 2.4 ml/kg/hr. Afebrile. Tracheal aspirate from 12/24 is final with no growth while the blood culture from 12/23 remains with no growth at this time. Current plan is to complete a minimum of 7 days of antibiotic therapy.</p> <p>Plan: Continue Gentamicin 12.5 mg IV every 24 hours infused over 30 minutes. Will obtain Gentamicin levels around the dose tonight with a goal peak of 7-10 mcg/ml and trough < 1.2 mcg/ml. Pharmacy will continue to monitor the patient's labs and renal function daily.</p> | Ex 9 000044- Ex 9 000045 |
| 12/26/YYYY | Provider/ Hospital | <p>@1419 hours: Lactation assessment:</p> <p>Feeding Plan: Mother to provide skin-to-skin contact, nuzzling, and direct breastfeeding when medically appropriate and as per physician orders. Mother to pump 8-10 times a day, on comfortable pump settings, for 20 minutes to establish and maintain milk supply. Encouraged proper cleansing in warm soapy water after each use and sterilization once daily of pump kit pieces. Sterilization bag at bedside. Call inpatient LC staff or the Family Resource Center for future lactation needs. Mother verbalized understanding.</p> | Ex 9 000046- Ex 9 000048 |
| 12/26/YYYY | Provider/ Hospital | <p>@2035 hours: Lumbar puncture procedure report:</p> <p>Indication: Rule out meningitis</p> <p>32 gauge spinal needle was inserted in the L4-L5 intervertebral space. The stylet was removed. A total of 4 ml of CSF was collected in different tubes and sent for routine studies, Herpes PCR and CSF amino acids.</p> | Ex 9 001284 |
| 12/26/YYYY | Provider/ Hospital | <p>@2216 hours: Progress notes:</p> <p>Current: Extubated on 12/26 NPO/TPN/IL FG keeping at 100. UAC/PICC. Plan feed morning. On Antibiotics. Plan 7 days. Follow CSF, blood, skin, TA culture. On Acyclovir. Follow skin, blood and CSF.</p> <p>Day of life: 3 Today's weight: 3150 gms Change: 20</p> <p>Head/Neck: Anterior fontanelle is soft and flat. No oral lesions. Neurologic: Slightly hypotonic. Reacts to touch with all limbs. No exaggerated jerks. Skin: The skin is pink and well perfused. No rashes, vesicles, or other lesions are noted. Caput with bruising.</p> | Ex 9 000049- Ex 9 000055 |

Patient 1
Patient 2

DOB: MM/DD/YYYY
DOB: MM/DD/YYYY

| DATE | FACILITY/ PROVIDER | MEDICAL EVENTS | BATES REF |
|------|-----------------------|---|-----------|
| | | <p>Active medications: Ampicillin Gentamicin Calcium gluconate Levetiracetam Lorazepam Acyclovir Phenobarbital</p> <p>Room air</p> <p>Blood culture – 12/23/YYYY – No growth Tracheal aspirate – 12/23/YYYY – No growth</p> <p>Nutrition support: NPO/TPN/IL UAC/UVC. FG 100. UAC/PICC UVC taken out (low). Plan beginning feeds tomorrow</p> <p>At risk for Hyperbilirubinemia 12/26/YYYY: 3.8 (0.4)</p> <p>Respiratory Diagnosis: Respiratory Insufficiency - onset <= 28 days Meconium Aspiration Syndrome Plan: 12/26/YYYY: Atelectasis improved. Stable in low SIMV settings. Extubated to RA.</p> <p>Sepsis-newborn-suspected Plan: 12/25/YYYY: Blood culture, ET Aspirate pending. Chest X-ray: Consistent with Meconium aspiration. Plan minimum 7 days antibiotics. LP cytology reassuring. CSF culture sent.</p> <p>Rule our Herpes - congenital No documented history of herpes. Poor perinatal transition with depression. Refractory seizures by EEG. LFT altered. HSV topical swabs sent on 12/24. Blood PCR for HSV sent on 12/25 and Acyclovir commenced on 12/25. Repeat topical swabs tomorrow AM. Plan: Continue Acyclovir until all blood, CSF, PCR and HSV culture come back.</p> <p>Hematology Plan: WCC 14.4, hematocrit 42.7, platelet 204, neutrophils 66, 1% band, lymphocyte 24</p> | |

Patient 1
Patient 2

DOB: MM/DD/YYYY
DOB: MM/DD/YYYY

| DATE | FACILITY/ PROVIDER | MEDICAL EVENTS | BATES REF |
|------------|-----------------------|--|-----------------------------|
| | | Neurology: Diagnosis: Perinatal depression Plan: 12/25/YYYY: Per EEG patient has improved with Keppra and Phenobarbital on board. Dr. Thalakoti advised MRI between day 8-10. LP done. CSF for amino acid sent. Patient is much more wakeful today. | |
| 12/27/YYYY | Provider/ Hospital | @0514 hours: X-ray of chest and abdomen: Impression: No significant interval change. | Ex 9 000410- Ex 9 000412 |
| 12/27/YYYY | Provider/ Hospital | @0935 hours: Pharmacy Progress Notes: Assessment: WBC 12. Scr 0.21. Urine output over past 24 hours of 1.8 ml/kg/hr. Afebrile. Blood and CSF cultures remain with no growth at this time. The tracheal aspirate is final with no growth. Obtained Gentamicin levels around the evening dose last night which resulted with a peak of 8.5 mcg/ml and trough of 0.5 mcg/ml. Both are within goal ranges. Plan: Continue Gentamicin 12.5 mg IV every 24 hours infused over 30 minutes. No further levels unless duration of therapy goes > 7 days or renal function/clinical status changes. Pharmacy will continue to monitor the patient's labs and renal function daily. | Ex 9 000056- Ex 9 000057 |
| 12/27/YYYY | Provider/ Hospital | Progress notes: Current: Extubated on 12/26 FG 110 on BW. TPN/PICC. Started gavage feeds. On Antibiotics. Plan 7 days. Follow CSF, blood, skin, TA culture. Discontinue Acyclovir. CSF and blood culture PCR negative. Skin culture negative. Day of life: 4 Today's weight: 3200 gms Change: 50 General: Active with stim. Decreased tone. Head/Neck: Anterior fontanelle is soft and flat. No oral lesions. Neurologic: Slightly hypotonic. Reacts to touch with all limbs. No exaggerated jerks. Skin: The skin is pink and well perfused. No rashes, vesicles, or other lesions are noted. Active medications: Ampicillin Gentamicin Calcium gluconate Levetiracetam Lorazepam Phenobarbital | Ex 9 000061- Ex 9 000067 |

Patient 1
Patient 2

DOB: MM/DD/YYYY
DOB: MM/DD/YYYY

| DATE | FACILITY/ PROVIDER | MEDICAL EVENTS | BATES REF |
|------------|-----------------------|--|--------------|
| | | <p>Room air</p> <p>Blood culture – 12/23/YYYY – No growth Tracheal aspirate – 12/23/YYYY – No growth Skin culture (HSV) – 12/24/YYYY – No growth Blood culture = 12/25/YYYY – No growth CSF culture – 12/26/YYYY – No growth</p> <p>Actual Intake: TPN Saline ½ normal SMOF lipids Route - OG</p> <p>Nutrition support: Infant has escalated resp support needs. Stabilized on CPAP 5. Mom declines PDHM and is pumping. Will start EMBM 20 cal 5 mls every 4 hours. Consider increasing volume and change to every 3 hours if stable in morning. FG 110 on BW. TPN/SMOF.</p> <p>At risk for Hyperbilirubinemia 12/27/YYYY: Bili 2.2</p> <p>Respiratory Infant requiring increasing support. Initially on HFNC 2 L/min with increasing O2 needs and tachypnea. To 4 L/min on - 40% O2, then to NCPAP 5. Improved on NCPAP 5 with decrease in O2 back to -26%. Comfortable continuing CPT every 4 hrs. Following ABG.</p> <p>Sepsis-newborn-suspected 12/27/YYYY: Blood culture, ET Aspirate negative. Chest X-ray – MAS. Minimum 7 days antibiotics.</p> <p>Rule out Herpes - congenital Plan: Blood, CSF PCR negative. Will discontinue Acyclovir and follow skin cultures.</p> <p>Hematology Plan: Hematocrit 42.4, platelet 235. No left shift. Will follow up on Monday 01/01.</p> <p>Neurology: 12/27/YYYY: Infant is still slightly hypotonic, back to CPAP due to poor oxygenation, suspect shallow breathing. Responds well to tactile stim, no b/t seizures. Remains on Keppra and Phenob.</p> | |
| 12/28/YYYY | Provider/ | @0430 hours: X-ray of chest and abdomen: | Ex 9 000413- |

Patient 1
Patient 2

DOB: MM/DD/YYYY
DOB: MM/DD/YYYY

| DATE | FACILITY/ PROVIDER | MEDICAL EVENTS | BATES REF |
|------------|-----------------------|--|-----------------------------|
| | Hospital | Impression: Stable examination. | Ex 9 000414 |
| 12/28/YYYY | Provider/ Hospital | <p>@0919 hours: Pharmacy Progress Notes:</p> <p>Assessment: Obtained Gentamicin levels around the evening dose on 12/26 which resulted with a peak of 8.5 mcg/ml and trough of 0.5 mcg/ml. Both are within goal ranges.</p> <p>Plan: Continue Gentamicin 12.5 mg IV every 24 hours infused over 30 minutes. No further levels unless duration of therapy goes > 7 days or renal function/clinical status changes. Pharmacy will continue to monitor the patient's labs and renal function daily.</p> | Ex 9 000068- Ex 9 000069 |
| 12/28/YYYY | Provider/ Hospital | <p>@1355 hours: Progress notes:</p> <p>Current: Extubated on 12/26 FG 110 on BW. TPN/PICC. Started gavage feeds. On Antibiotics. Plan 7 days. Follow CSF, blood, skin, TA culture. Discontinue Acyclovir. CSF and blood culture PCR negative. Skin culture negative. Was on HFNC, increased O2 needs requiring back to NCPAP 5. Improved. Chest X-ray in morning.</p> <p><i>Other assessment and plan remains the same as that of progress note on 12/27/YYYY.</i></p> | Ex 9 000069- Ex 9 000076 |
| 12/28/YYYY | Provider/ Hospital | <p>@1824 hours: Progress notes:</p> <p>Current: Extubated on 12/26 FG 140 on BW. Advancing feeds as able MBM or Enfamil or BF. On Antibiotics. Plan 7 days. Follow CSF, blood, skin, TA culture. Discontinue Acyclovir. CSF and blood culture PCR negative. Skin culture negative. Was on HFNC, increased O2 needs requiring back to NCPAP 5. Now back to LFNC on 12/28.</p> <p>Day of life: 5 Today's weight: 3190 gms Change: -10</p> <p>General: Active and alert. Head/Neck: Anterior fontanelle is soft and flat. Neurologic: Decreased tone and activity.</p> <p>Active medications: Ampicillin Gentamicin</p> | Ex 9 000083- Ex 9 000089 |

Patient 1
Patient 2

DOB: MM/DD/YYYY
DOB: MM/DD/YYYY

| DATE | FACILITY/ PROVIDER | MEDICAL EVENTS | BATES REF |
|------------|-----------------------|--|-----------------------------|
| | | <p>Calcium gluconate Levetiracetam Lorazepam Phenobarbital</p> <p>Settings for nasal canula: FiO2 1, flow 0.2 L</p> <p>Blood culture – 12/23/YYYY – No growth Tracheal aspirate – 12/23/YYYY – No growth Skin culture (HSV) – 12/24/YYYY – No growth Blood culture = 12/25/YYYY – No growth CSF culture – 12/26/YYYY – No growth HSV CSF – 12/26/YYYY – No growth HSV PCR rectal – 12/26/YYYY – No growth</p> <p>Actual Intake: TPN Breast milk Enfamil LIPIL with Fe Saline ½ normal SMOF lipids</p> <p>Respiratory Discontinue CPT. Wean to LFNC. Discontinue UAC.</p> <p>Sepsis – newborn – suspected: Blood culture and ETA negative. Chest X-ray – MAS. Minimum 7 days antibiotics. Last doses likely 12/30</p> <p>Neurology: 12/28/YYYY: Last seizure 12/26. MRI to be done 12/30. Urine organic acids. CSF for AA pending. Serum amino acid showed elevated methionine. Will draw a homocysteine and another plasma AA before pulling UAC. Home on Keppra and Phenobarb Level ordered for Monday Level 35.3 on 12/27.</p> | |
| 12/28/YYYY | Provider/ Hospital | <p>@1859 hours: Progress notes:</p> <p>Day of life: 5 Today's weight: 3190 gms Change: -10</p> <p>Settings for nasal canula: FiO2 1, flow 0.2 L</p> <p>Nutrition: 12/28/YYYY: FG 140 on BW. Increase 10 ml every 12 hrs. MBM or Enfamil or BF. Poor oral interest so will get therapy involved.</p> | Ex 9 000077- Ex 9 000083 |

Patient 1
Patient 2

DOB: MM/DD/YYYY
DOB: MM/DD/YYYY

| DATE | FACILITY/ PROVIDER | MEDICAL EVENTS | BATES REF |
|------------|-----------------------|--|-----------------------------|
| | | <i>Other assessment and plan remains the same as that of progress notes on the same day at 1824 hours</i> | |
| 12/28/YYYY | Provider/ Hospital | <p>@1902 hours: Nursing Notes:</p> <p>Parents at bedside from 1100, assisting in cares. Bath given, mother experiencing breast discomfort, infant will trial BF when RS 1,2. Lactation referral requested.</p> <p>Infant showed improved muscle tone, but is still weak response and is RS 3 and 4 through cares. Does not exhibit hunger cues or interest in pacifier. Tolerating feeds. Trialing LFNC, VS stable at end of shift.</p> | Ex 9 000076 |
| 12/29/YYYY | Provider/ Hospital | <p>@0515 hours: Progress Notes:</p> <p>Infants UAC removed at this time. Catheter intact Pressure applied for 5 min and pressure dressing applied at this time.</p> | Ex 9 000089 |
| 12/29/YYYY | Provider/ Hospital | <p>@1153 hours: Occupational Therapy evaluation:</p> <p>Neurobehavioral/neurosensory assessment: Motor: Extension movements: extremities, trunk, symmetric, asymmetric Flexion Movements: Extremities, trunk, facial, symmetric, asymmetric Quality: Sluggish Tone: Low-normal State: Diffusely awake but drowsy unpredictable cycles</p> <p>Neuromotor assessment: Posture: Legs slightly flexed UE Recoil: Arm flexes slowly UE Traction: Arm flexes slightly-some resistance felt LE Recoil: Complete fast flexion LE Traction: Leg flexes slightly-some resistance felt Head Lag: Head drops and stays back Plantar Grasp: Toes flex slightly Pal mar grasp: Short, weak flexion of fingers Startle: Negative</p> <p>Feeding assessment: GI: Currently getting 25 ml MBM 20 cal every 3 hours and advancing by 10 ml every 12 hours Other medical: Apnea, seizures Feeding schedule: Every 3 hours Nutrition/Hydration and method: TPN, IV</p> <p>Non-Nutritive Suck Observation pacifier therapist gloved finger Jaw/Tongue ROM: Decreased organization on the nipple Lip Seal: Decreased closure around utensil Suck Strength: Weak Suck Characteristics: Rhythmic</p> | Ex 9 000091- Ex 9 000096 |

Patient 1
Patient 2

DOB: MM/DD/YYYY
DOB: MM/DD/YYYY

| DATE | FACILITY/ PROVIDER | MEDICAL EVENTS | BATES REF |
|------------|-----------------------|---|--|
| | | <p>Summary of findings: Patient is working towards robustness during ADL's with physiologic, motor and state stability. She required CPR at birth with Apgars of 1, 6 & 9. She experienced apnea and involuntary movements after 6 hours of life, requiring intubation. EEG confirmed seizure activity. She was successfully extubated 12/26 and has been seizure-free since that date with medication. She has shown poor interest in oral feedings until now. Mom is pumping and planning to breast feed. Dad at bedside during OT eval. Patient aroused with handling and gradual increase of stimulation. She began opening eyes, moving all 4 extremities, turning head side to side and rooting. She attempts to bring hands to mouth. Her ROM is WNL. Reflexes are sluggish for PMA and tone is slightly low. She was unable to lift or turn head in prone. She opened mouth for pacifier and sucked rhythmically but suck is weak and bursts are brief. She is managing all secretions, no suctioning needed. Now that UAC has been removed, RN approved holding, nuzzling and skin-to-skin.</p> <p>Discussed recommendation with Dad and RN that patient should attempt nuzzling at fully-pumped breast for as many touch times as Mom can be present. Encouraged holding skin-to-skin frequently by both parents, offering pacifier and providing soothing auditory stimulation. Dad and RN in agreement. Made plan to meet with parents tomorrow and determine if patient is showing enough oral interest to offer tastes while nuzzling at empty breast.</p> <p>Plan of care: OT will continue to follow 3 times per week addressing robustness during participation in occupation as evidenced by physiologic, motor and state stability.</p> <p>Discharge recommendations: Equipment needed at discharge: will determine at a later date, closer to discharge. Recommendations for referral to another service: NICU therapy follow-up clinic. Evaluation by Missouri First Steps Program for developmental follow-up.</p> | |
| 12/29/YYYY | Provider/ Hospital | <p>@1335 hours: Pharmacy Progress Notes:</p> <p>All cultures are negative to date.</p> <p>Plan: Continue Gentamicin 12.5 mg (4 mg/kg) IV every 24 hours infused over 30 minutes. No further levels will be obtained unless therapy continued beyond 12/31 or there is a ;change in patient's renal function.</p> | Ex 9 000096- Ex 9 000098 |
| 12/29/YYYY | Provider/ Hospital | <p>@1406 hours: EEG report:</p> <p>Medications: Phenobarb and Keppra.</p> | Ex 9 000110- Ex 9 000111, Ex 9 000111- |

| DATE | FACILITY/ PROVIDER | MEDICAL EVENTS | BATES REF |
|------------|-----------------------|---|-----------------------------|
| | | <p>EEG Interpretation: This is an abnormal EEG with predominant right focal and central focal seizure activity suggestive of predominant right frontal focus, but there are also left frontal temporal activities noted, suggestive of multifocal onset over a depressed low voltage background activity, suggestive of diffuse cerebral dysfunction. There is subclinical seizure activity but it reduced from midnight, less frequently to rarely noted the next day. The background activity showing slight improvement with improved voltage activity with bursts but still has interburst discontinuity prior to discontinuing the EEG.</p> | Ex 9 000113 |
| 12/29/YYYY | Provider/ Hospital | <p>@1416 hours: Physical Therapy evaluation:</p> <p>History: RN reports that infant does move all extremities, but does seem to be low tone. Reports alertness at touch times varies. Infant potentially going to nuzzle at empty breast this touch time. Parents not present initially but did arrive towards end of evaluation.</p> <p>Musculoskeletal: A-ROM: Actively moves all extremities, but decreased than expected for PMA Quality of movement: Smooth Quantity of movement: Decreased than expected for current PMA Cranial Observations: Appears symmetrical</p> <p>Neurological - Posture, Tone, & Reflexes: Posture: Arms and legs flexed but abducted Scarf: Resistance at contralateral axillary line UE Recoil: Arm flexes slowly, arm flexes partially UE Traction: Arm flexes slightly-some resistance felt LE Recoil: Leg flexes slowly, leg flexes partially LE Traction: Leg flexes well till bottom lifts up Popliteal Angle : Approximately 130 degrees Head Lag: Head drops and stays back Head Raising in Prone: Lifts head slightly, does not fully clear surface Plantar Grasp: Toes flex slightly on right, unable to test on left secondary to IV Palmar grasp: Short, weak flexion of fingers Galant: (+), Strength of response varies Suck: Some sucking on hand observed</p> <p>Assessment: Infant displays decreased tone, reflexes, and active movements than expected for PMA. All reflex responses are present but weak. She does actively move all extremities but with decreased anti-gravity movements and return to an abducted position at rest. No attempts to lift head during pull to sit and weak attempts to lift head in prone position. Infant did remain very drowsy throughout session.</p> | Ex 9 000098- Ex 9 000102 |

Patient 1
Patient 2

DOB: MM/DD/YYYY
DOB: MM/DD/YYYY

| DATE | FACILITY/ PROVIDER | MEDICAL EVENTS | BATES REF |
|------------|-----------------------|---|-----------------------------|
| | | Recommendations: Therapy Frequency: Will follow 5 times per week. Following discharge home, infant to be seen in NICU Follow-up Clinic by OT and PT and evaluation by Missouri First Steps Program for developmental follow-up. | |
| 12/29/YYYY | Provider/ Hospital | @1539 hours: Progress notes: Current: FG 140 on BW. Advancing feeds as able MBM or Enfamil or BF. On Antibiotics. Plan 7 days. EEG positive for seizures. On Keppra and Phenobarbital. MRI ordered for 12/30. Day of life: 6 Today's weight: 3220 gms Change: 30 Neurologic: Decreased tone and activity Active medications: Ampicillin Gentamicin Calcium gluconate Levetiracetam Lorazepam Phenobarbital Settings for nasal canula: FiO2 1 Skin culture (HSV) – 12/26/YYYY – No growth Actual Intake: TPN Breast milk Enfamil LIPIL with Fe Saline ½ normal SMOF lipids Route – Gavage/PO Nutrition support: Diagnosis: Nutritional support, Feeding problem – slow feeding 12/29/YYYY: Dec FG 100 ml/k/day then continue increase in feeds to max 140 ml/k/d PO/gavage, OT involved. All gavage. Respiratory: Room air today | Ex 9 000102- Ex 9 000108 |

Patient 1
Patient 2

DOB: MM/DD/YYYY
DOB: MM/DD/YYYY

| DATE | FACILITY/ PROVIDER | MEDICAL EVENTS | BATES REF |
|------------|-----------------------|--|-----------------------------|
| | | Cardiovascular: Stable Sepsis-newborn-suspected 12/29/YYYY: Discontinue antibiotics tomorrow. Neurology: Patient is more wakeful today. Serum AA quantitative-> mild elevation of methionine-recommendation - send another sample-> will consider sending Tuesday, urine organic acid screen - N-acetyltyrosine detected - could be due to TPN. | |
| 12/30/YYYY | Provider/ Hospital | @0808 hours: Pharmacy Progress Notes: All cultures are negative to date. Current plan is 7 days of therapy with stop times placed and last doses to be given this evening. Plan: Continue Gentamicin 12.5 mg (4 mg/kg) IV every 24 hours infused over 30 minutes. No further levels will be obtained unless therapy continued beyond 12/31 or there is a change in patient's renal function. | Ex 9 000113- Ex 9 000115 |
| 12/30/YYYY | Provider/ Hospital | @1451 hours: Progress notes: Current: FG 140 on BW. MBM or Enfamil PO/NG. Completed antibiotics 12/30. Room air as of 12/29 Day of life: 7 Today's weight: 3230 gms Change: 10 Neurologic: Decreased tone and activity but improved. Active medications: Levetiracetam Phenobarbital On room air Actual Intake: Breast milk Enfamil LIPIL with Fe Nutrition support: 12/30/YYYY: Increasing feeds to max 140 ml/k/d PO/gavage, OT/ST/PT involved. Mainly gavage. Respiratory: Stable in room air | Ex 9 000118- Ex 9 000123 |

Patient 1
Patient 2

DOB: MM/DD/YYYY
DOB: MM/DD/YYYY

| DATE | FACILITY/ PROVIDER | MEDICAL EVENTS | BATES REF |
|------------|-----------------------|---|-----------------------------|
| | | Sepsis-newborn-suspected 12/30/YYYY: Discontinue antibiotics today. Neurology: Last seizure 12/26. MRI to be done 12/30. CSF for AA neg. Serum amino acid showed elevated methionine. Homocysteine level normal and another plasma AA before pulling UAC was drawn and pending. Home on Keppra and Phenobarb. Level ordered for Monday. Level 35.3 on 12/27, urine organic acid screen – N-acetyltyrosine detected - could be due to TPN. | |
| 12/30/YYYY | Provider/ Hospital | @1510 hours: MRI of brain with and without contrast: Findings: Midline structures not well evaluated but appear grossly normal. There are fairly extensive areas of abnormal T2 signal and diffusionopathy involving the corpus callosum and periventricular white matter tracts, centrum semiovale and also the cerebral cortices bilaterally, left greater than right. Findings are consistent with hypoxic ischemic injury given history. Postcontrast images show scattered amorphous enhancement about the cortices likely posts ischemic inflammatory. No critical mass effect or significant secondary hemorrhage. There does appear to be some petechial gyral hemorrhage over the frontal convexities. Major intracranial arterial flow voids are preserved. Impression: Limited study due to motion. Finding consistent with anoxic ischemic injury as described in detail above. No critical mass effect. | Ex 9 000415- Ex 9 000420 |
| 12/31/YYYY | Provider/ Hospital | @1041 hours: Progress notes: Current: FG 140 on BW. MBM or Enfamil PO/NG. Completed antibiotics 12/30. Room air as of 12/29 Day of life: 8 Today's weight: 3200 gms Change: -30 Neurologic: Decreased tone and activity but improved. Active medications: Levetiracetam Phenobarbital On room air Actual Intake: Breast milk | Ex 9 000124- Ex 9 000129 |

Patient 1
Patient 2

DOB: MM/DD/YYYY
DOB: MM/DD/YYYY

| DATE | FACILITY/ PROVIDER | MEDICAL EVENTS | BATES REF |
|------------|-----------------------|---|-----------------------------|
| | | <p>Enfamil LIPIL with Fe</p> <p>Nutrition support: 12/30/YYYY: Increasing feeds to max 140 ml/k/d on CW PO/gavage, OT/ST/PT involved. Mainly gavage.</p> <p>Hematology: CBC to be done today with PICC removal.</p> <p>Neurology: Diagnosis: Perinatal depression Seizures Comment: Urine organic acid and CSF AA unremarkable Hypoxic-ischemic encephalopathy (moderate)</p> <p>Last seizure 12/26. MRI shows fairly extensive areas per radiology report of ischemic injury. Will repeat EEG on 1/2. Needs neuro consult this week. First steps referral placed.</p> | |
| 01/01/YYYY | Provider/ Hospital | <p>@1415 hours: Progress notes:</p> <p>Day of life: 9 Today's weight: 3230 gms Change: 30</p> <p>Neurologic: Decreased tone and activity but improved.</p> <p>Active medications: Levetiracetam Phenobarbital</p> <p>On room air</p> <p>Actual Intake: Breast milk Enfamil LIPIL with Fe</p> <p>Nutrition support: 01/01/YYYY: Increasing feeds to max 140 ml/k/d on CW PO/gavage, OT/ST/PT involved. Mainly gavage – 34% per oral</p> <p>Hematology: CBC 12/31/ benign</p> <p>Neurology: Last seizure 12/26. Phenobarb level 42.7 on 12/31. First steps referral placed. Neuro consulted and will see likely 01/02.</p> | Ex 9 000133- Ex 9 000137 |
| 01/02/YYYY | Provider/ | @0817 hours: Neurology consultation report: | Ex 9 000153- |

| DATE | FACILITY/ PROVIDER | MEDICAL EVENTS | BATES REF |
|------|-----------------------|--|-------------|
| | Hospital | <p>History of present illness: Baby is a 39 week 6 day gestational age white female who was born to a 28 yr, G1 P0 A0 mom on 12/23/17. After birth baby was not breathing right and she thinks she required some resuscitation secondary to meconium aspiration. Then she seemed to be okay for a few hours then began having respiratory difficulty. EPIC review revealed admission of a six hour old infant who had turned dusky and was having repeated periods of desaturation necessitating NCPAP. Birth history suggestive of poor transition necessitating CPR for approx. 3 minutes with perinatal meconium exposure. The infant was intubated and ventilated for ongoing desaturation episodes. Mercy Transport team noted involuntary movements. EEG was subsequently performed and she was placed on Keppra and Phenobarb and tolerating well.</p> <p>Physical examination: Vitals: BP 77/56, pulse 150, temp 98.9, resp. rate 38, SpO2 100% Height 52.5 cm Weight 3094 g Head circumference 35 cm 86%ile based on WHO (Girls, 0-2 years) length-for-age data using vitals from 1/1/YYYY. 17%ile based on WHO (Girls, 0-2 years) weight-for-age data using vitals from 1/3/YYYY. 3%ile based on WHO (Girls, 0-2 years) BMI-for-age data using weight from 1/3/YYYY and height from 1/1/YYYY. 57%ile based on WHO (Girls, 0-2 years) head circumference-for-age data using vitals from 1/3/YYYY.</p> <p>Neurologic examination: Facial muscles appeared symmetric. Good suck On motor exam, patient had normal bulk and mildly increased tone, with symmetric, asynchronous, antigravity movement throughout. Sensation was normal to touch. Deep tendon reflexes brisk and symmetric bilaterally. Mora, Rooting, babinski, Plantar/palmar grasp intact On coordination exam, mild jitteriness noted.</p> <p>Assessment: Baby is 11 days female with a cerebral hypoxic/ischemic injury. The MRI revealed fairly extensive areas of abnormal T2 signal and diffusionopathy involving the corpus callosum and periventricular white matter tracts, centrum semiovale and also the cerebral cortices bilaterally, left greater than right. In addition, recent EEG revealed epileptiform discharges seen independently in the bilateral temporal regions.</p> <p>Given these findings, she is at risk for developmental difficulties and neurological sequela from the hypoxic injury. Monitoring for these</p> | Ex 9 000159 |

| DATE | FACILITY/ PROVIDER | MEDICAL EVENTS | BATES REF |
|------------|-----------------------|--|-----------------------------|
| | | <p>difficulties over time and intervening will be imperative. This was discussed with the parents.</p> <p>Recommendations:</p> <ol style="list-style-type: none"> 1. Continue current dosing of Keppra and Phenobarb 2. Referral to First Steps to continue ST, OT, PT 3. She needs an ophthalmologic exam due to the posterior predominance of her brain injuries that may affect cortical vision 4. Follow up appointment with Pediatric Neurology one month from discharge. | |
| 01/02/YYYY | Provider/ Hospital | <p>@1353 hours: Speech Therapy evaluation:</p> <p>Subjective information: Staff Concerns: Fatigue at breast, weight loss Patient/Family Perspective: Mother wants to breast-feed baby and take her home. Mother prefers to avoid pacifier use and formula feedings. She was tearful and expressed that she felt situation was her fault, but declined to talk about it further.</p> <p>Swallow evaluation: Primary Swallowing Complaint: Slow feeding progression; mother breast-feeds daytime and bottle is offered at night when mother not present. Previous Level of Feeding and Swallowing: Patient has taken 10-20 ml at breast per ac/pc weights. PO intake is about 35%.</p> <p>Oral musculature assessment: Oral/Facial Characteristics: Hypotonic-mild Secretion Management: Swallows own secretions Quality of Voice/Cry: WNL Rooting Reflex: Present Cough Reflex: Present</p> <p>Nutritive suck observations: Liquid delivery method: Breast Positioning: Semi-sidelying, full sidelying Suck Strength: Fair ROM: Decreased organization on the nipple, decreased lingual groove, wide jaw excursions and "chomping" movements Signs of Feeding Stress: Coughing, pulling/turning away from breast and stridor Coordination/Swallow: Coughing, disorganized suck/swallow/breathe, gulping, high-pitched crowing, poor endurance and wet vocalizations Hypersensitive Behaviors/Aversion: Head turning and wriggling</p> <p>Assessment: 1300: Met with lactation, RN and parents at bedside. Lactation assisted mother with latch. Mother had not pumped prior to feeding. Observed gulping, stridor and wet-sounding respirations when patient in semi-</p> | Ex 9 000149- Ex 9 000153 |

Patient 1
Patient 2

DOB: MM/DD/YYYY
DOB: MM/DD/YYYY

| DATE | FACILITY/ PROVIDER | MEDICAL EVENTS | BATES REF |
|------------|-----------------------|---|-----------------------------|
| | | <p>sidelying position, improved with repositioning in full sidelying with head-neck-trunk aligned per SLP verbal cues. Mother also reported that latch felt better after patient repositioned. Patient quickly fatigued at breast, taking 26 ml in 12 min.</p> <p>Provided education re positioning and swallow coordination at breast. Mother in agreement with SLP assessing swallow during bottle-feeding 1/3. Recommend either BF/NG or bottle/NG for now while patient building skill and endurance.</p> <p>Compensatory swallowing strategies and therapeutic interventions attempted: Positional changes.</p> <p>Recommendations: Current Diet: Breast Milk Infant Formula (20 Enfamil)</p> <p>Feeding/swallow guidelines: For Readiness Score of 1 or 2: May breast-feed per lactation recommendations OR may bottle-feed as follows: Position: Swaddle with hands near face, side-lying, with head-neck-trunk aligned Bottle: Dr. Brown's Ultra Preemie bottle-nipple Interventions: External pacing PRN and rest breaks as needed Limit feedings to 30 minutes Offering breast- and bottle- in same feeding not recommended at this time due to limited endurance.</p> <p>Discharge recommendations: Recommend patient discharge to be determined closer to discharge. Recommendations for referral to another service: OT, PT, and lactation are involved</p> | |
| 01/02/YYYY | Provider/ Hospital | <p>@2012 hours: Progress notes:</p> <p>Current: Stable in room air FG 140 on BW, MBW or Enfamil per oral/NG Status post antibiotics. Status post Acyclovir. Neuro to see patient tomorrow.</p> <p>Day of life: 10 Today's weight: 3130 gms Change: -100</p> <p>Neurologic: Significantly improved tone and activity.</p> <p>Active medications:</p> | Ex 9 000143- Ex 9 000148 |

Patient 1
Patient 2

DOB: MM/DD/YYYY
DOB: MM/DD/YYYY

| DATE | FACILITY/ PROVIDER | MEDICAL EVENTS | BATES REF |
|------------|-----------------------|--|-----------------------------|
| | | <p>Levetiracetam Phenobarbital</p> <p>On room air</p> <p>Actual Intake: Breast milk Enfamil LIPIL with Fe Route: OG/Per oral</p> <p>Nutrition support: 01/02/YYYY: Mother is trying hard to breast feed and baby getting better at it. OT/PT helping with transition. PO/NG Fg 140</p> <p>Hematology: CBC 12/31/ benign</p> <p>Neurology: Neuro to see patient tomorrow. Follow repeat serum for amino acids. Home on Keppra and Phenobarb. Phenobarb level 42.7 on 12/31. EEG noted for epileptiform discharges but negative for seizures.</p> | |
| 01/03/YYYY | Provider/ Hospital | <p>@1704 hours: Speech Therapy Record:</p> <p>Therapeutic intervention/treatment assessment: PO intake has been 36%, 40% past 2 days. Ac/pc weights have improved to about 20 ml. Patient receives bottle overnight when mother is not available to breast-feed.</p> <p>1300 feeding: Parents away and MGF holding patient at bedside. SLP offered 20 MBM and 20 Enfamil by Dr Brown's bottle. Started with Ultra Preemie and offered trial faster Preemie and Dr Brown's Specialty bottle due to frequent ineffective non-nutritive sucking and slow rate of intake. Dysfunctional suck pattern of non-nutritive sucking persisted with all trials. Patient took 29 ml in 30 minutes.</p> <p>1600 feeding: Repeat trial Dr. Brown's Specialty bottle (Ultra Preemie and Preemie nipples) discontinued due to aversive behaviors including pulling away, pushing nipple with tongue, and allowing milk to leak at corners when offered. Repositioned infant sidelying with her back to SLP to provide increased support and containment. Offered standard Dr. Brown's bottle with Preemie nipple. Patient exhibited improved suck organization and took 34 ml in 20 minutes. Intermittent stridor and wet-sounding respirations noted.</p> <p>1850: Met with mother at bedside after her return to provide update re bottle trials and recommendations. Encouraged mother to keep breast-feeding and reviewed education re combining breast- and bottle-feedings to achieve full oral feedings when appropriate.</p> | Ex 9 000171- Ex 9 000174 |

Patient 1
Patient 2

DOB: MM/DD/YYYY
DOB: MM/DD/YYYY

| DATE | FACILITY/ PROVIDER | MEDICAL EVENTS | BATES REF |
|------------|-----------------------|--|---|
| | | Agree with change to 24 cal Enfamil formula to provide slightly thicker consistency to support improved swallow safety. | |
| 01/03/YYYY | Provider/ Hospital | <p>@1731 hours: Progress notes:</p> <p>Day of life: 11 Today's weight: 3094 gms Change: -36</p> <p>Neurologic: Improved tone and activity.</p> <p>Active medications: Levetiracetam Phenobarbital</p> <p>On room air</p> <p>Actual Intake: Breast milk Enfamil LIPIL with Fe Route: OG/Per oral</p> <p>Nutrition support: 01/03/YYYY: Per oral 40% on mostly 20 cal Enfamil -> Change to 24 cal Enfamil decrease FG 130</p> <p>Neurology: Dr. Collins came to talk to parents this morning.</p> | Ex 9 000166- Ex 9 000171 |
| 01/04/YYYY | Provider/ Hospital | <p>@1331 hours: Final Physical Therapy Record:</p> <p>Treatment dates: 01/01/YYYY, 01/04/YYYY</p> <p>Subjective: Infant gets sleepy before finishing bottles.</p> <p>Treatment: Infant displays active flexion of extremities during diaper change and cares performed by RN and Mom. LEs flex well with hips in abduction; flexes UEs and brings hands to mouth/midline. Good resistance to traction of LEs and recoils into flexion after passive extension of UEs and LEs.</p> <p>Infant transferred to Mom for bottle feeding; Mom preferred to not swaddle infant, but blanket placed under her in case swaddling for organization would be necessary. Mom also preferred to place infant supine on a pillow in her lap for feeding. Infant begins sucking bottle after a few seconds of bottle being offered, infant appears to not get a good latch on the bottle nipple and each suck/swallow is audible (stridorous sound?). After several sucks infant chokes; mom stops feeding and holds</p> | Ex 9 000177- Ex 9 000179, Ex 9 000130- Ex 9 000132 |

Patient 1
Patient 2

DOB: MM/DD/YYYY
DOB: MM/DD/YYYY

| DATE | FACILITY/ PROVIDER | MEDICAL EVENTS | BATES REF |
|------------|-----------------------|---|---|
| | | <p>infant upright. At this time, this therapist asked the mom if she ever fed infant in side-lying; she answered no, but said she would try it. She placed infant side-lying facing her and continued feeding. Sounds of stridor decreased with side-lying position.</p> <p>Assessment/plan: Continue with POC as patient does require skilled PT for neurodevelopmental progression. Patient is progressing towards care plan goals.</p> | |
| 01/04/YYYY | Provider/ Hospital | <p>@1637 hours: Progress notes:</p> <p>Day of life: 12 Today's weight: 3116 gms Change: 22</p> <p>Neurologic: Normal tone and activity.</p> <p>Active medications: Levetiracetam Phenobarbital</p> <p>On room air</p> <p>Actual Intake: Breast milk 20 cal Enfamil LIPIL with Fe 24 cal</p> <p>Nutrition support: 01/04/YYYY: Tolerating full feeds of 24 cal MBM fortified with Enfamil or 24 cal Enfamil. Feeding goal 130 on 3.1kg. PO/NG + BF with AC/PC weights. PO 68%</p> <p>Neurology: Normal tone and activity. Eye exam ordered for 1/5 per Collin's request</p> | Ex 9 000181- Ex 9 000185 |
| 01/05/YYYY | Provider/ Hospital | <p>@1052 hours: Final Occupational Therapy evaluation:</p> <p>OT treatment performed on: 12/30/YYYY, 01/04/YYYY</p> <p>Assessment: Patient is working towards age-appropriate and skillful participation in the following occupation/co-occupations: Pre-feeding, socialization and visual attention, pre-play development/skill Strengths contributing to participation in meaningful occupation include: supportive physical environment, supportive social environment, consistent caregivers, family interaction Barriers limiting participation in meaningful occupation include: sensory function, bone and joint integrity, movement/motor skill, motor function/reflexes, physiologic stability, state stability, processing skills,</p> | Ex 9 000188- Ex 9 000190, Ex 9 000115- Ex 9 000117, Ex 9 000174- Ex 9 000177 |

Patient 1
Patient 2

DOB: MM/DD/YYYY
DOB: MM/DD/YYYY

| DATE | FACILITY/ PROVIDER | MEDICAL EVENTS | BATES REF |
|------------|-----------------------|---|-----------------------------|
| | | <p>communication/behavioral In support of predictability and continuity, self-soothing, timing/pacing, environmental support, positioning/handling/movement, sleeping/awake time/socialization, participation in occupation the following recommendations are made: Please offer 1-2 minutes of Tummy Time at each touch time for alerting and strengthening. For RS 1-2, please swaddle and slowly transition to sidelying while baby sucks her pacifier. May breast feed OR may offer Dr. Brown's bottle with Preemie nipple. Positioning in side-lying facing away from caregiver seems to provide more support and may help her better organize effective suck when bottle-feeding (tends to do a lot of ineffective non-nutritive sucking).</p> <p>Occupations addressed today: Pre-feeding, socialization and visual attention, pre-play development/skills</p> | |
| 01/05/YYYY | Provider/ Hospital | <p>@1443 hours: Ophthalmology Consultation:</p> <p>Baby is a 13 days Caucasian female who had fetal distress and evidence of seizure-like activity following delivery. Some MRI abnormalities of brain were noted. An eye examination was recommended to rule out ocular abnormalities.</p> <p>Objective: Visual Acuity: OD: Reacts to light OS: Reacts to light</p> <p>Drops: Mydriacyl 1% one drop OU at 12:00</p> <p>Pupils: 5 mm OU reactive briskly to 3 mm OU; no RAPD</p> <p>Tension: Normal to finger tension OU</p> <p>Motility: Full OU; ocular alignment is orthophoric (limited exam to spontaneous movements only).</p> <p>Assessment: Normal ocular structures OU.</p> <p>Plan: 1. No treatment currently indicated from ophthalmic standpoint 2. Will plan to recheck visual function in 6 months (sooner if concerns develop over failure to meet visual developmental milestones)</p> | Ex 9 000191- Ex 9 000193 |
| 01/05/YYYY | Provider/ Hospital | <p>@2255 hours: Progress notes:</p> | Ex 9 000194- Ex 9 000199 |

Patient 1
Patient 2

DOB: MM/DD/YYYY
DOB: MM/DD/YYYY

| DATE | FACILITY/ PROVIDER | MEDICAL EVENTS | BATES REF |
|------------|-----------------------|---|-----------------------------|
| | | <p>Day of life: 13 Today's weight: 3107 gms Change: -9</p> <p>Neurologic: Active with variable tone.</p> <p>Active medications: Levetiracetam Phenobarbital</p> <p>On room air</p> <p>Actual Intake: Breast milk 20 cal Enfamil LIPIL with Fe 24 cal</p> <p>Nutrition support: 01/05/YYYY: Lost weight with loss for the week, however remains above BW. Will adjust goal to 140 on CW. PO/NG+ BF with AC/PC weights. PO 57%.</p> <p>Neurology: Active with variable tone. Eye exam ordered for 1/5 per Collins request-->no concerns. Will plan to recheck visual function in 6 months per Cascairo.</p> | |
| 01/06/YYYY | Provider/ Hospital | <p>@ 1210 hours: Progress notes:</p> <p>Day of life: 14 Today's weight: 3126 gms Change: 19</p> <p>Neurologic: Active with variable tone.</p> <p>Active medications: Levetiracetam Phenobarbital</p> <p>On room air</p> <p>Actual Intake: Breast milk 20 cal Enfamil LIPIL with Fe 24 cal</p> <p>Nutrition support: 01/06/YYYY: Gained 19 gms. No change in volume. PO slowly improving. -62%. MBM fortified with Enfamil or Enf 24 cal. No change.</p> <p>Neurology:</p> | Ex 9 000200- Ex 9 000205 |

Patient 1
Patient 2

DOB: MM/DD/YYYY
DOB: MM/DD/YYYY

| DATE | FACILITY/ PROVIDER | MEDICAL EVENTS | BATES REF |
|------------|-----------------------|---|-----------------------------|
| | | Active with variable tone. Eye exam ordered for 1/5 per Collins request-->no concerns. Will plan to recheck visual function in 6 months per Cascairo. | |
| 01/07/YYYY | Provider/ Hospital | <p>@1614 hours: Progress notes:</p> <p>Current: Stable in room air. Tolerating full feeds of 24 cal MBM fortified with Enfamil or 24 cal Enfamil. PO AL counting day 2 out of 3 today. Earliest discharge should be Tuesday.</p> <p>Day of life: 15 Today's weight: 3106 gms Change: -20</p> <p>Neurologic: Active with variable tone.</p> <p>Active medications: Levetiracetam Phenobarbital</p> <p>On room air</p> <p>Actual Intake: Breast milk 20 cal Enfamil LIPIL with Fe 24 cal</p> <p>Nutrition support: 01/07/YYYY: Took all PO yesterday. Will take NG out, made POAL today will count as day 2/3.</p> <p>Neurology: Active and alert.</p> | Ex 9 000209- Ex 9 000214 |
| 01/08/YYYY | Provider/ Hospital | <p>@2217 hours: Progress notes:</p> <p>Day of life: 16 Today's weight: 3151 gms Change: 45</p> <p>Neurologic: Active with variable tone.</p> <p>Active medications: Levetiracetam Phenobarbital</p> <p>On room air</p> <p>Actual Intake:</p> | Ex 9 000214- Ex 9 000220 |

| DATE | FACILITY/ PROVIDER | MEDICAL EVENTS | BATES REF |
|------------|-----------------------|--|-----------------------------|
| | | <p>Breast milk 20 cal Enfamil LIPIL with Fe 24 cal</p> <p>Nutrition support: 01/08/YYYY: PO feeding adlib. Gained weight and adequate volume intake. Earliest home possibility tomorrow.</p> <p>Neurology: Diagnosis: Perinatal depression Seizure – Urine organic acid and CSF AA unremarkable. Home on Phenobarbital and Keppra as prescribed. Hypoxic-ischemic encephalopathy (moderate) – Possibility of short term and long term neurological delay and dysfunction.</p> <p>01/08/YYYY: Active and alert. Script for Phenobarb and Keppra given to parents for home use.</p> <p>Parental support: Parents updated regards our concern for long term neurological developmental delay. Parents ask appropriate questions. Parents updated To CBP from tonight.</p> <p>Discharge planning: James Collins – Pediatric Neurologist on 02/09 First Step - To be arranged Peds – Dr. Catherine Benbow (Family Practice) – on 01/11/YYYY Cascairo – On 07/05/YYYY Alan Tong – Pediatric Cardiologist – 03/23/YYYY</p> | |
| 01/09/YYYY | Provider/ Hospital | <p>Discharge Summary:</p> <p>Admit date: 12/23/YYYY</p> <p>Birth weight: 3090 (11-25%tile) gm Birth head circumference: 35 (26-50%tile) cm Birth length: 52 (51-75%tile) cm</p> <p>Discharge weight: 3148 gm Discharge head circumference: 36 cm Discharge length: 52 cm</p> <p>Discharge medications: Levetiracetam 60 mg per oral three times daily Phenobarbital 12 mg (3/4 tab) per oral twice daily</p> <p>Discharge fluids: Brest milk – with term formula powder to 24 cal Enfamil LIPIL with Fe 24 cal formula</p> | Ex 9 000220- Ex 9 000231 |

Patient 1
Patient 2

DOB: MM/DD/YYYY
DOB: MM/DD/YYYY

| DATE | FACILITY/ PROVIDER | MEDICAL EVENTS | BATES REF |
|-------------------------------|-----------------------|---|-----------|
| | | <p>Discharge Physical Exam: Vitals: BP 97.6, resp. rate 42, BP 90/74, SpO2 100%</p> <p>Bed Type: Open Crib. General: Pale pink. Head/Neck: Awake, Alert. Improved activity, tone and perfusion. The head is normal in size and configuration. The fontanelle is fiat, open, and soft. Suture lines open. Bilateral retinal red reflex elicited. Nares are patent without excessive secretions. No of the oral cavity or pharynx are noticed. Chest: Breath sounds are equal bilaterally. Heart: Regular rate and rhythm, without murmur. Femoral pulses palpable. Abdomen: The abdomen is soft, non-tender, and nor-distended. Extremities: No deformities noted. Neurologic: Active with variable tone.</p> <p>At risk for hyperbilirubinemia: Not jaundiced at discharge Respiratory: Stable in room air at discharge. No events of significance. Cardiovascular: Hemodynamically stable. Follow up as outpatient for VSD with Dr. Tong Neurology: Active and alert. Script for Phenobarbital and Keppra given to parents for home use. Close followup as outpatient.</p> <p>Discharge Comment: This 3090 gram Birth Weight 39 week 6 day gestational age white female was born to a 28 yr. G1 P0 A0 mom. Perinatal depression and Acidosis Resolved with treatment over the past two weeks. 1. Home with biologic parents 2. Home on adlib PO feeding 24 cal Maternal breast milk fortified with term powder or Term 24 cal formula 3. Home on Anticonvulsants Phenobarbital and Keppra as prescribed. 4. Follow-up appointment with Primary care physician and specialists as arranged. 5. Parents decline Hepatitis B vaccination - to be considered along with two month immunization.</p> | |
| 12/23/YYYY - 01/09/YYYY | Provider/ Hospital | <p>Other related records:</p> <p>Assessment, plan of care, patient education, Labs, orders, mediation sheets, Flow Sheet</p> <p>Bates Ref: Ex 9 000002-Ex 9 000012, Ex 9 000014-Ex 9 000015, Ex 9 000035-Ex 9 000037, Ex 9 000032-Ex 9 000033, Ex 9 000044, Ex 9 000048-Ex 9 000049, Ex 9 000129, Ex 9 000055-Ex 9 000061, Ex 9 000132-Ex 9 000133, Ex 9 000089-Ex 9 000091, Ex 9 000108-Ex 9 000109, Ex 9 000123-Ex 9 000124, Ex 9 000137-Ex 9 000143, Ex 9 000148-Ex 9 000149, Ex 9 000166, Ex 9 000187-Ex 9 000188, Ex 9</p> | |

Patient 1
Patient 2

DOB: MM/DD/YYYY
DOB: MM/DD/YYYY

| DATE | FACILITY/ PROVIDER | MEDICAL EVENTS | BATES REF |
|------------|-----------------------|---|---|
| | | 000232-Ex 9 000244, Ex 9 000248-Ex 9 000393, Ex 9 000421-Ex 9 001326, Ex 9 000199-Ex 9 000200, Ex 9 000206-Ex 9 000209, Ex 9 000186-Ex 9 000187, Ex 9 000179-Ex 9 000180 | |
| 01/11/YYYY | Provider/ Hospital | <p>Office visit for well child visit:</p> <p>Chief complaint: 2 week WCC.</p> <p>Interval History/Parent & Child Concerns: NICU, Mother brings patient in for NICU discharge follow up. Originally transferred for apnea and hypoxia. Now on anti-seizure medications. Has pending follow ups with cardiology and neurology. Mother unsure of discharge weight. Reports she has been without seizures since discharge on 1/9/18.</p> <p>Child Care: Home with parents.</p> <p>Nutrition: Formula (Breast feeding every 2.5-3 hours. She does receive some pumped milk and formula at some feedings if she does not eat well).</p> <p>Development Personal Social and Language: Minimal Skills: Ability to be soothed, Regards face, Responds to voice/bell, Cries/makes sound.</p> <p>Fine Motor/Gross Motor: Minimal Skills: Equal movements, Follows to midline.</p> <p>Physical examination: No acute distress.</p> <p>Neurologic: Alert, Normal motor function, Moves all extremities appropriately, No focal deficits.</p> <p>Impression and Plan: Diagnosis: Well baby, 8 to 28 days old. Course: Progressing as expected.</p> <p>Plan: Discussed reading benefits including language development and bonding. Read books to your baby every day. Discussed supervised tummy time and back to sleep recommendations. Will await NICU discharge summary. Send referral for lactation to work on breastfeeding latch. Discussed vitamin D recommendations if no longer taking any formula. Return for next scheduled well baby check. Keep specialist follow up appointments. Recheck in two weeks at 1 month of age. Call sooner with questions or concerns. Diet: Breast milk.</p> | Ex 2 000853- Ex 2 000855 |
| 01/11/YYYY | Provider/ Hospital | <p>Individualized Family Service Plan (IFSP):</p> <p>Present level of development: Wake-up: Developmental areas: Adaptive, social/emotional, communication Patient sleeps in a crib in her parent's room. She will wake up between 6 and 7 AM. Her parents know when she is waking up because she will start making noises. Patient is starting to stay awake more during the day but</p> | Ex 5 000021- Ex 5 000027, Ex 5 000001- Ex 5 000002, Ex 5 000117 |

Patient 1
Patient 2

DOB: MM/DD/YYYY
DOB: MM/DD/YYYY

| DATE | FACILITY/ PROVIDER | MEDICAL EVENTS | BATES REF |
|------------|-----------------------|---|---|
| | | <p>still sleeps most of the day.</p> <p>Mealttime: Developmental areas: Adaptive, cognitive Patient takes a bottle every 2½ to 3 hours. She is latching onto the bottle and doesn't have any leakage from the sides of her mouth. Patient is on breastmilk most of the time and takes it from a bottle. It takes her 20 to 30 mins to finish a bottle.</p> <p>Play: Developmental areas: Social/emotional, communication Kelsey gives patient tummy time before her feedings. Patient is starting to lift her head for a few seconds and can turn it both directions. She does not like being in a room if she cannot see someone in there with her. When patient is on her back she will kick her feet. She is starting to make eye contact and responds to Kelsey's voice. Patient will make cooing sounds and is making different cries to get her needs and wants met. Patient likes to be held and walked around the house. Patient brings both hands to her mouth and sucks on them. She will also respond to Kelsey's voice.</p> | |
| 01/17/YYYY | Provider/ Hospital | <p>Office visit for rash:</p> <p>History of present illness: Patient presents with mother due to concern for rash on her face. She has been eating well and having regular wet diapers. She is smiling spontaneously. She is tracking things with her eyes. She is lifting her head when she is on her belly. She is moving her arms and legs equally.</p> <p>Assessment/Plan: Toxic erythema of newborn. Discussed normal newborn rashes. Given online resources to consult that are trustworthy. Discussed reasons to return to clinic or call. Return for next well baby check.</p> | Ex 2 000834- Ex 2 000835, Ex 2 000836- Ex 2 000849 |
| 01/25/YYYY | Provider/ Hospital | <p>Office visit for well child visit:</p> <p>Chief complaint: 1 month WCE.</p> <p>Interval History/Parent & Child Concerns: Does not have a bowel movement every day. Nutrition: Formula (eating pumped breast milk 2.5 oz every 2-3 hours, will go 4 hours at night). Output: Toileting Development Personal Social and Language: Minimal Skills: Ability to be soothed, Regards face, Responds to voice/bell, Cries/makes sound. Fine Motor/Gross Motor: Minimal Skills: Equal movements, Follows to midline, lifts head while prone (by report).</p> <p>Physical examination: Weight 7.69 lb (3.5 kg)</p> | Ex 2 000812- Ex 2 000814, Ex 2 000815- Ex 2 000832 |

Patient 1
Patient 2

DOB: MM/DD/YYYY
DOB: MM/DD/YYYY

| DATE | FACILITY/ PROVIDER | MEDICAL EVENTS | BATES REF |
|------------|-----------------------|--|---|
| | | <p>Head circumference: 14 inch</p> <p>Neurologic: Alert, Normal motor function, Moves all extremities appropriately, No focal deficits, Hand grasp present, Toe grasp present, Response to stimulation.</p> <p>Impression and Plan:</p> <p>Diagnosis Well baby exam, over 28 days old.</p> <p>Course: Progressing as expected.</p> <p>Plan: Discussed reading benefits including language development and bonding. Read books to your baby every day. Continue keeping your baby rear facing in a car seat until two years of age or he/she outgrows the height and weight recommendations for the car seat. Continue to talk, play and sing with your baby. Advised not to have any screen time at this point including TV, computers, smart phones or tablets. Return for next scheduled well baby check. Reviewed back to sleep and tummy time and vitamin D recommendations. Has neurology appt in two weeks. Will refill medications. Mother will call in with correct dosing. Discussed ways to manage constipation including rectal temp and rectal stimulation. Discussed normal stooling.</p> <p>Diet: Age appropriate diet, Breast milk.</p> | |
| 01/26/YYYY | Provider/ Hospital | <p>Referral report:</p> <p>Speech therapy: Evaluate and treatment</p> | Ex 2 000673- Ex 2 000674 |
| 01/31/YYYY | Provider/ Hospital | <p>Speech/Language Assessment:</p> <p>Parent Report: Mom reported that patient has a very good suck swallow/breathe reflex when eating. She said she does not have feeding concerns. Patient cries when she is hungry or uncomfortable.</p> <p>Observations/Clinical impressions: Patient moved her arm and legs and looked at the evaluator's face when she spoke. She cried briefly and took the rest of her bottle and then calmed.</p> <p>Facial expressions: Starting to show some</p> <p>Oral motor structures/speech: Observations/Clinical Impressions: An interview with mom indicated that the structure and function of the oral mechanism indicates that it appears to be adequate for feeding and speech at this time. When she takes her bottle, her suck/swallow/breathe pattern is good. She makes some mild gasping noises when eating. She is able to keep her pacifier in. There are no concerns at this time regarding oral motor structure or function.</p> | Ex 5 000008- Ex 5 000011, Ex 5 000012- Ex 5 000016 |

| DATE | FACILITY/ PROVIDER | MEDICAL EVENTS | BATES REF |
|------------|-----------------------|---|---|
| | | <p>Eating and swallowing: Mom reported that patient takes her bottle well and is gaining weight. She also nurses occasionally. She does make some gasping noises when eating, but they are not concerning at this time. She takes approximately 2.5 ounces per feeding in about 20-30 minutes.</p> <p>Fine Motor: Patient had her thumbs out most of the time and gripped the evaluator's finger when placed in her hand.</p> <p>Gross Motor: Patient tolerated being on her tummy on the evaluator's lap for a few seconds. She lifted her head up from a slightly inclined position and turned it to both sides. She had good head control for her age and could turn her head to both sides. She moved her arms and legs. She demonstrated the ATNR reflex.</p> <p>Summary of assessment results: Patient is a very sweet baby girl who is already moving a lot. She is taking her bottles and gaining weight. She is alert for a good amount of time for her age and crying to get her needs met. She seems to recognize caregivers and calms to them. Her parents are following up with several specialists given her trauma at and after her birth. The seizure medication she is on seem to be controlling the seizures effectively.</p> <p>Recommendations, suggestions, and strategies: 1. Continue to follow up with the appropriate specialists. 2. Follow up with OT to monitor development due to history of trauma at birth. 3. Contact service coordinator if other concerns arise.</p> | |
| 02/07/YYYY | Provider/ Hospital | <p>Referral report:</p> <p>Occupational therapy: Evaluate and treatment</p> | Ex 2 000676 |
| 02/09/YYYY | Provider/ Hospital | <p>Pediatric Neurology visit for NICU follow up:</p> <p>She has been doing well since home. She has been on Levetiracetam and Phenobarb without side effects. Outpatient OT has been started with first steps. Feeding is going well. Parents have no questions or concerns today.</p> <p>Physical examination: Weight 3945 gm (14%tile) Head circumference 34.5 cm (10%tile) BMI 13.87 (17%tile)</p> <p>Assessment and plan: Baby is a 6 weeks old female with a cerebral hypoxic ischemic injury. The MRI revealed fairly extensive areas of abnormal T2 signal and diffusionopathy involving the corpus callosum and periventricular white matter tracts, centrum semiovale and also the cerebral cortices bilaterally, left greater than right. In addition, the EEG revealed epileptic form</p> | Ex 2 000500- Ex 2 000505, Ex 2 000506- Ex 2 000509 |

| DATE | FACILITY/ PROVIDER | MEDICAL EVENTS | BATES REF |
|------------|-----------------------|--|---|
| | | <p>discharges seen independently in the bilateral temporal regions. Given these findings, she is at risk for developmental difficulties and neurological sequelae from the hypoxic injury. She has been on Levetiracetam and Phenobarb since discharge and has been seizure free.</p> <p>Recommendation:</p> <ol style="list-style-type: none"> 1. Begin wean of Phenobarb 2. Continue Levetiracetam 60 mg thrice daily (45.6 mg/kg/day) 3. If breakthrough seizures, will increase Levetiracetam 4. Continue therapies 5. We have discussed the prognosis, pathophysiology and treatment risk vs benefits in today's visit. Parent's questions have all been answered. 6. Return in about 3 months (around 5/9/YYYY). 7. Orders placed as follows: Phenobarbital 20 mg/5 ml (4 mg/ml) Elixir. Levetiracetam (Keppra) 100 mg/ml Solution. | |
| 02/23/YYYY | Provider/ Hospital | <p>Office Visit for well child exam:</p> <p>Chief complaint: 1 month WCE.</p> <p>Interval History/Parent & Child Concerns: No Concerns. Has seen the peds neurologist and they are weaning her off her seizure medications. Has follow up in May. Has been seen by the occupational therapy and has some home exercises to do. Sleeping: Sleeping well at night and longer stretches. Nutrition: Formula (eating every 2-3 hours going longer at night now. She will take up to 3 oz of expressed breast milk).</p> <p>Fine Motor/Gross Motor: Minimal Skills: Equal movements, Follows to midline, Lifts head 45 degrees while prone (by report).</p> <p>Weight 4 kg (8.81 lb) Head circumference: 14.2 inch Neurologic: Alert, Moves all extremities appropriately, No focal deficits.</p> <p>Impression and Plan: Diagnosis: Well baby, over 28 days old. Course: Progressing as expected.</p> <p>Plan: Discussed reading benefits including language development and bonding. Read books to your baby every day. Continue keeping your baby rearfacing in a car seat until two years of age or he/she outgrows the height and weight recommendations for the car seat. Continue to talk, play and sing with your baby. Advised not to have any screen time at this point including TV, computers, smart phones or tablets. Return for next scheduled well baby check. Continue to keep appointment with ped, ophto and peds neuro and follow instructions given from the occupational</p> | <p>Ex 2 000790- Ex 2 000792, Ex 2 000793- Ex 2 000810</p> |

Patient 1
Patient 2

DOB: MM/DD/YYYY
DOB: MM/DD/YYYY

| DATE | FACILITY/ PROVIDER | MEDICAL EVENTS | BATES REF |
|------------|-----------------------|---|-----------------------------|
| | | <p>therapist. We discussed tummy time, vitamin D supplementation and back to sleep. Immunizations declined today. May return at any time for a nurse visit if parents change their mind.</p> <p>Diet: Age appropriate diet, Breast milk.</p> | |
| 03/22/YYYY | Provider/ Hospital | <p>EKG report:</p> <p>Sinus rhythm Normal EKG</p> | Ex 6 000010 |
| 03/23/YYYY | Provider/ Hospital | <p>Cardiology consultation:</p> <p>Diagnosis: Very small muscular Ventricular Septal Defect (VSD).</p> <p>History of present illness: Cardiac evaluation with history of heart murmur and abnormal echo. She had a history of difficult regular delivery and was transferred to the Mercy Springfield NICU, where she stayed for 17 days. She had neonatal seizures and is on Keppra and weaning doses of Phenobarbital. She has a posterior brain injury by imaging that is being followed but she is doing well since her discharge.</p> <p>Weight: 4.53 kg (<3%) Height 55.88 cm (3%)</p> <p><i>Diagnostic studies were reviewed and presented below</i></p> <p>Impression: Ventricular septal defect.</p> <p>Plan and recommendations: Echocardiogram-focused in 9 months. No cardiovascular restrictions necessary. Follow-up visit in 9 months. (Echocardiogram). Sub-acute bacterial endocarditis prophylaxis is not required for this condition. Dietary recommendations include regular. She appears well and her muscular VSD is very small by echo. It has a high likelihood of spontaneously closing.</p> <p>Follow-up in 1 year.</p> | Ex 2 000787- Ex 2 000789 |
| 03/23/YYYY | Provider/ Hospital | <p>Echocardiogram:</p> <p>Indication: History of abnormal echo</p> <p>Procedure: Echo congenital complete with color flow Doppler and spectral Doppler.</p> <p>Conclusion: Very small muscular VSD, normal LV function and size.</p> | Ex 6 000006- Ex 6 000007 |

Patient 1
Patient 2

DOB: MM/DD/YYYY
DOB: MM/DD/YYYY

| DATE | FACILITY/ PROVIDER | MEDICAL EVENTS | BATES REF |
|------------|-----------------------|--|---|
| 04/24/YYYY | Provider/ Hospital | Telephone Conversation: Mom Kelsay called regarding referral from Dr. Susan Inman to Dr. Cascairo. Patient does have an appt that was made in January for a six month follow up from the hospital for July. This referral was recently made. Mom is stating that patient doesn't want to look to the right. Says they can turn her head to the right to look at something but she will turn it right back to the right. Says OU not tracking, OD>OS. Please review about what to do. | Ex 8 000002- Ex 8 000004 |
| 04/26/YYYY | Provider/ Hospital | Follow-up visit for well child exam: Chief complaint: 4 month WCE. Development Personal Social and Language: Minimal Skills: Vocalizes (by report): Responsive smile, Laughs/squeals (by report), uses voice to show emotions, "OOH/AAH" (by report), responds to touch. Emerging Skills: Recognizes parent, Babbles/Coos. Fine Motor/Gross Motor: Follows midline with her L eye. R eye does not. Minimal Skills: Grasps rattle/toy, Head up 90 degrees, Pulls to sitting position, head steady. Emerging Skills: Rolls back to front. Hearing: Awakes to loud noise, Head turning with noise Physical examination: Weight 4.75 kg General: No acute distress, Laughing and squealing and making vocalizations during exam. Unable to make eye contact with patient. Eye: Normal conjunctiva, Unable to get patient to track any objects during visit. HENT: Oral mucosa is moist, Mild parallelogram head noted on exam with prominence on the anterior forehead on the left. Neurologic: Alert, Oriented, Normal motor function, No focal deficits. Impression and Plan: Diagnosis: Well baby, over 28 day old. Weight below third percentile. Course: Noted to have deficit of L eye movement and does not turn to the L. Plan: Advised mother to get routine immunizations. She is well aware of the safety and benefits of this but her husband does not wish to have their | Ex 2 000754- Ex 2 000756, Ex 2 000757- Ex 2 000774 |

Patient 1
Patient 2

DOB: MM/DD/YYYY
DOB: MM/DD/YYYY

| DATE | FACILITY/ PROVIDER | MEDICAL EVENTS | BATES REF |
|------------|-----------------------|--|---|
| | | daughter immunized. I let her know she may return anytime for a nurse visit to get this done if desired. Keep Neurology and Ophthalmology appointments as scheduled. Discussed position to help with shape of head. Noted decrease head circumference on growth chart. Continue frequent tummy time. Decreased on weight growth percentile too. Will have mother also supplement with formula to give additional calories. If not improving will get blood work. Recheck in 3-4 weeks. | |
| 05/09/YYYY | Provider/ Hospital | Office Visit for eye exam: History: Mom states the patient doesn't want to turn her head to the right. Mom's afraid she can't see that direction. Mom states she doesn't track very well either. She states she also doesn't focus on anything for very long & doesn't make eye contact. Mom states the patient was full term. Last seizure in 12/YYYY. Coarse following behavior; had characteristics of oculomotor apraxia without head thrusting behavior. Intermittent exotropia confirms vision for both eyes. I did see intermittently a tendency toward tonic deviation of both eyes to the left side, though at other times, patient demonstrated full motility. Plan: 1. No treatment currently from ophthalmic standpoint; I would expect to see improving visual function over next few months. 2. Return in about 3 months (around 8/9/YYYY). | Ex 8 000009- Ex 8 000011, Ex 8 000005- Ex 8 000009, Ex 8 000011- Ex 8 000017, Ex 2 000751- Ex 2 000753, Ex 8 000119- Ex 8 000120 |
| 05/23/YYYY | Provider/ Hospital | Pediatric Neurology follow up visit: No side effects of Levetiracetam. She is off the phenobarbital mid-April. She has been doing pretty good. She was not wanting to look to the right. The eye muscle are probably not develop related to stroke. But not a cortical vision loss. She does have constipation. Developmental history: She is rolling over, she is not reaching for objects. She is not bringing toys to midline. She is smiling, laugh, cooing. She is moving all side equally. She likes social games. She is not tracking well, no concerns about her hearing. No problems with feeding. Bottle feeds with breast milk. She is in 1st step currently. Vision therapy. Physical examination: Weight 4.99 kg (<1%tile) Height 84.8 cm (63%tile) Head circumference 38 cm (<1%tile) Neurologic Examination: Patient was alert Pupils were equal, round and reactive to light and extraocular movements | Ex 2 000487- Ex 2 000492, Ex 2 000493- Ex 2 000495, Ex 2 000499 |

Patient 1
Patient 2

DOB: MM/DD/YYYY
DOB: MM/DD/YYYY

| DATE | FACILITY/ PROVIDER | MEDICAL EVENTS | BATES REF |
|------------|-----------------------|--|-----------------------------|
| | | <p>were intact. Kept her head turned to the left as well as gaze but will go to midline and two the right.</p> <p>On motor exam, patient had normal bulk and tone with symmetric, tended to keep the right arm in flexed position, the left arm was moving more.</p> <p>On coordination exam, mild jitteriness noted.</p> <p>Assessment:</p> <p>Baby is a 5 month old female with a diffuse cerebral hypoxic/ischemic injury. There are signs of developmental delay and she tends to have a left gaze preference and does not use the right arm as much as the left arm. She has been seizure free since hospitalization. She has been so far successfully weaned of the Phenobarbital. She is on monotherapy Keppra without side effects. She is currently in the appropriate therapies.</p> <p>Recommendations:</p> <ol style="list-style-type: none"> 1. Discussed AED management, will get EEG if normalized then will begin weaning off the Keppra 2. Continue Levetiracetam 60 mg thrice daily (45.6 mg/kg/day) 3. Continue therapies. 4. We have discussed the prognosis, pathophysiology and treatment risk vs benefits in today's visit. 5. Return in about 3 months 6. Orders placed as follows: <p>EEG: Sleep Deprived. Levetiracetam (Keppra) 100 mg/ml solution.</p> | |
| 05/31/YYYY | Provider/ Hospital | <p>Office visit for weight check:</p> <p>History of Present Illness:</p> <p>Here for weight check.</p> <p>Eating 4 oz of formula mixed with water as well as getting breast milk. She eats every 3 hours. Sometimes she will eat 5 oz. Having regular wet and dirty diapers.</p> <p>Weight: 11.06 lb</p> <p>Assessment/Plan:</p> <p>Decreased growth</p> <p>Discussed nutrition goals and reviewed growth curve. Will plan to increase number of calories in formula feeding. Due to spitting up unable to increase amount of feeding.</p> <p>Recheck at next visit. Given handout on mixing formula to increase calories.</p> | Ex 2 000711 |
| 06/11/YYYY | Provider/ Hospital | Telephone Conversation regarding appointment scheduling | Ex 2 000103- Ex 2 000104 |
| 06/15/YYYY | Provider/ Hospital | <p>Office Visit for Functional vision evaluation:</p> <p>Visual Medical History:</p> | Ex 5 000029- Ex 5 000031 |

| DATE | FACILITY/ PROVIDER | MEDICAL EVENTS | BATES REF |
|------|-----------------------|--|-----------|
| | | <p>Joy Anna is under the care of Dr. Mark Cascairo, a pediatric ophthalmologist. He feels that baby's eye muscles are developing slowly.</p> <p>Functional vision: Assessment environment: Joy Anna was assessed in her grandparent's home with her mother and grandmother present. Her grandfather and uncle were also there, although they were in another room most of the time. The room was well lit with natural light through large windows.</p> <p>Appearance of the eye: General Appearance: The globes, orbits, irises and pupils of the eyes appeared normal in size and shape. Nystagmus (involuntary movement of the eyes): Nystagmus was not observed. Viewing Mode and head tilt: Baby demonstrated a definite preference for looking to the left. She repeatedly turned her head to the left during the assessment. Her family reports that she loves to look outside. The windows were to her left, but her family says that when you turn her so the windows are to the right, she doesn't necessarily turn that direction. Alignment: There was some slight inward drifting of both eyes.</p> <p>Ocular Motility (eye movement skills): Fixation: Baby is able to hold brief fixation. Tracking: Baby is able to track, but eye movements are not smooth. Gaze Shift: Gaze shift is present. Scanning: Scanning is not present, but this is not a skill we would expect to see at baby's age. Convergence and Divergence: Convergence develops before divergence. Some beginning convergence was observed, but it was not consistent. Divergence was not observed, but baby is still a little young.</p> <p>Summary: Baby is a five month old girl who is experiencing some visual delays. She is not making consistent eye contact and tracking, while emerging, is not smooth. Because of her young age, it is possible that these skills will develop as she matures. However, it is felt that she would benefit from direct services from a Teacher of the Visually Impaired (TVI).</p> <p>Recommendations and Suggestions: The following suggestions are made for baby family and service providers. The TVI providing direct services will give additional suggestions as needed. Approach patient from the right side to encourage her to turn in that direction. Likewise, present visual targets from the right. Toys with music and lights may encourage her to do more reaching. Move objects slowly through the visual field to encourage smooth tracking.</p> | |

| DATE | FACILITY/ PROVIDER | MEDICAL EVENTS | BATES REF |
|------------|-----------------------|--|---|
| 06/27/YYYY | Provider/ Hospital | <p>Office Visit for well child visit:</p> <p>Chief complaint: 6 month WCC – parent declines to vaccinate.</p> <p>Development Personal Social and Language: Minimal Skills: Laughs (by report), Squeals (by report), Attachment to caretaker. Emerging Skills: Recognizes parent, Imitates razzing.</p> <p>Fine Motor/Gross Motor: Minimal Skills: Rolls over (by report). Emerging Skills: Bears weight, No head lag, Grasp and mouthing.</p> <p>Physical examination: Weight 5.37 kg Height 25.75 inch Head circumference 15.25 inch</p> <p>Tongue tie present with heart shaped tongue but it is able to be thrust out past the lower lip margin. Head rotated to the L and able to be passively rotated to the R by mother.</p> <p>Neurologic: Alert, Moving arms and legs independently. Does not make eye contact during exam.</p> <p>Impression and Plan: Diagnosis: Decreased growth. Well baby, over 28 day s old. Seizure disorder.</p> <p>Course: Continued weight below the 3rd percentile as well as continued head circumference below the 3rd percentile with weight in the 50th percentile. She has increased concentration of formula feedings to 22 cal.</p> <p>Plan: Father continues to decline immunizations. Mother would like to get them if he was agreeable. Diet: Age appropriate diet, Milk-based formula, Increase formula to 24 cal concentration. Will update neurology regarding head circumference in the 3rd percentile. Continue care with neurology, optho, PT /OT. Blood work to further evaluate failure to thrive. Consider GI referral depending on results. Will call with results when available.</p> | Ex 2 000670- Ex 2 000672, Ex 2 000678- Ex 2 000696 |
| 07/08/YYYY | Provider/ Hospital | Telephone Conversation regarding referral for tongue issue | Ex 2 000641- Ex 2 000643 |
| 07/25/YYYY | Provider/ Hospital | Telephone Conversation regarding labs | Ex 2 000625- Ex 2 000626 |
| 08/02/YYYY | Provider/ Hospital | Telephone Conversation regarding labs | Ex 2 000084- Ex 2 000085 |
| 08/14/YYYY | Provider/ | Ophthalmology Visit: | Ex 8 000029- |

| DATE | FACILITY/ PROVIDER | MEDICAL EVENTS | BATES REF |
|------------|-----------------------|---|---|
| | Hospital | <p>Chief complaint: Delayed visual maturation.</p> <p>History: Patient's mom states that she thinks that she is tracking things a little bit better. She states that sometimes her right eye will still drift out, and that is causing some problems with her tracking.</p> <p>Current medications: Keppra 100 mg/ml</p> <p>Intermittent exotropia moderately well controlled currently. Still has some oculomotor apraxic visual behaviors and a tendency toward eccentric fixation.</p> <p>Diagnosis: Exotropia, intermittent. Regular astigmatism of both eyes. Delayed visual maturation.</p> <p>Plan: 1. No treatment currently from ophthalmic standpoint; I would expect to see improving visual function over next few months. 2. Return in about 4 months.</p> | Ex 8 000034, Ex 8 000024- Ex 8 000028, Ex 2 000393- Ex 2 000394, Ex 8 000113- Ex 8 000114 |
| 08/15/YYYY | Provider/ Hospital | <p>Consultation for developmental delay:</p> <p>Subjective: 7-month-old female here for developmental evaluation. There is some concern for her growth. She was born at term via C-section for failure to descend. Mom was group B strep positive but didn't get antibiotics longer than 4 hours prior to delivery. After delivery the Apgars were 1 at 1 minute, 6 at 5 minutes and 9 at 10 minutes. At about 10 hours of life she started having some desaturations in the newborn nursery which ultimately went down to the 50s on her pulse ox and required intubation and transfer to the NICU. She did spend a couple of weeks and then NICU, she was having some seizures and started on Phenobarbital and ultimately switched to Keppra. They did get this under control with Phenobarbital. Mom states she had normal head ultrasounds but the MRI of her brain was abnormal somewhat in the posterior region. Mom did not mention any intraventricular hemorrhage, this was all done at Mercy NICU.</p> <p>She did get followed by Dr. Collins the pediatric neurologist and the pediatric Ophthalmologist as well who has been monitoring her visual acuity. She does have some strabismus going on. As far as mom knows her newborn screen is normal. She did have some reflux for which they put her on Zantac. Mom states she is breast-fed for the most part, they did give her supplement to increase the breast milk to 24-calorie. She is</p> | Ex 2 000570- Ex 2 000572, Ex 2 000580- Ex 2 000600 |

| DATE | FACILITY/ PROVIDER | MEDICAL EVENTS | BATES REF |
|------|-----------------------|---|-----------|
| | | <p>putting this in the bottle as well. The child does have a tight frenulum apparently. Mom states she is not the best at latching on to the breast so they are putting in bottles. She has normal stools. She stools about once a day and she has urine output about every 2-3 hours. She states that she sleeps pretty well through the night from 9-5 AM without difficulty. Her initial weight was 6 lbs 13oz. Her weight today is 12-1/4 pounds. She does continue to have seizure activity and is being followed by paediatric neurology.</p> <p>Assessment:</p> <p>1. Developmental delay (Unspecified lack of expected normal physiological development in childhood).</p> <p>Assessment and plan:</p> <p>1. Developmental delay, decreased growth, tongue tied Her weight today was 12-1/4 pounds which is not quite a doubling of her birth weight. Typically they will double their birth weight by 6 months and then triple at by a year. Looking at her birth weight plotted on a growth curve, she did start off 25% for weight, by 2 months she moved down to the 10th percentile and now she is well below the 3rd percentile for weight. Her length started off somewhere between 75th and 50th percentile as well and has moved to the 10th percentile for length. Her head circumference was initially 35 cm at birth and by 2 months had gone below the 5th percentile, now she is below the 3rd percentile for head circumference. Her height has been the one thing that has maintained the most stability but every parameter has dropped.</p> <p>Mom states that her breast milk does look kind of watery, she is mostly using breast milk with the fortifier to increase the milk to a 24-calorie amount. Developmentally, she is rolling over, she is making good eye contact she is making appropriate noises. The Apgar at 1 minute is not ideal. If she did have some anoxic hit to the head that certainly could explain some of her visual issues and maybe some of her feeding issues. I do think she has failure to thrive, based on her growth chart trajectories, she looks like she is calorie deficient. Her weight drops off pretty early followed by her height, but her head actually drops off almost in the same way that her weight does. If the anoxic injury to the brain could be causing the microcephaly if that is the cause of inadequate brain growth. Don't have any of the records on the paternal side of the children who had failure to thrive. In the short-term we did discuss with mom switching to actual formula instead of breast milk. If she is not actually making enough nutritious or calorically dense milk even the fortifier is not going to create enough calories for the child to grow.</p> <p>We did give her away to mix the formula so we get a 24-calorie per ounce formula concentration and have her eat her 4-5 ounces every 3 hours. Mom will call me in about a week to see if we cant get a weight on her. They will weigh her at home on their scale and then weigh her in a week</p> | |

Patient 1
Patient 2

DOB: MM/DD/YYYY
DOB: MM/DD/YYYY

| DATE | FACILITY/ PROVIDER | MEDICAL EVENTS | BATES REF |
|------------|-----------------------|--|---|
| | | <p>to see if this is making any difference. There are a number of labs that we can get done but at this point.</p> <p>2. Decreased growth (Other lack of expected normal physiological development in childhood)</p> <p>Follow up in 1 month.</p> | |
| 08/22/YYYY | Provider/ Hospital | <p>Telephone Conversation regarding tongue frenectomy:</p> <p>Patient is doing great, had the tongue frenectomy this morning and doing well with that, not spitting up as much after starting Zantac. She is napping at the moment, will weigh her after she wakes up and let us know.</p> <p><i>*Reviewer's comment: Direct report for frenectomy performed on this day is not available for review.</i></p> | Ex 2 000128- Ex 2 000129 |
| 08/29/YYYY | Provider/ Hospital | <p>Office visit for upper respiratory infection:</p> <p>Chief Complaint: Parents report cough, congestion, green nasal drainage, febrile x 1 week.</p> <p>Physical exam: Weight: 12.69 lb</p> <p>Assessment/Plan: Viral URI with cough (Acute upper respiratory infection) Discussed typical course of viral illness of 7-10 or 14 days. Encouraged to monitor respiratory status and hydration. Call if not improving in the expected time course.</p> | Ex 2 000550, Ex 2 000551- Ex 2 000563 |
| 09/06/YYYY | Provider/ Hospital | <p>Follow up visit:</p> <p>History of present illness: Subjective: 8-month-old female here for failure to thrive reevaluation. At the last visit about 2 weeks ago we had mom increase to only formula and do 24-calorie formula first and then offer some breast milk supplement. Mom states she did try her on breast milk and even looked at it and it was incredibly watery so she discontinued using breast milk at all. The baby is eating 5-1/2 ounces every 3-4 hours and then sleeping 8 hours a night. That puts her at about 22-25 ounces of formula a day. She also is getting some baby food She did have a frenulectomy by Dr. Cash and states she started eating so much better, she was coping down the bottles and seemed to have less frustration with feeds. We did start the Zantac and that seems to be working nicely as well. She is no longer spitting up, Houston launcher food and now any spit up is just a slight dribble and very minimal at that. She has had a couple of minor illnesses since the last visit with runny nose and congestion where she was not eating as much. She is smiling and happy, she is rolling over both ways at night, mom will let her on her back but she finds her on her stomach or her side in the morning. She is taking out her feet nicely and she will stop both her head and her</p> | Ex 2 000512- Ex 2 000514, Ex 2 000515- Ex 2 000523 |

| DATE | FACILITY/ PROVIDER | MEDICAL EVENTS | BATES REF |
|------|-----------------------|---|-----------|
| | | <p>feet while she is lying on her stomach to look around. She leaves the head well above the torso when trying to sit up. He is grabbing fingers well. Mom has also been giving her some baby food and she seems not to have any problems with any of this so far.</p> <p>Assessment and plan: 1. Developmental delay (Unspecified lack of expected normal physiological development in childhood:</p> <p>Failure to thrive. For the most part she is pretty developmentally appropriate. She might be a little behind on a couple things but nothing too far right now.</p> <p>We did plot her growth chart again, starting from birth she was about 75% in length and now has dropped below the 5% percentile. Some of this could be measurement error but definitely the trend is too smaller. Her weight started at about 25th percentile at birth and has dropped well below the 3th percentile, however she has gained weight over the last 20 days. So the chart shows an uptrend. Her head circumference started at 50% at birth and is well below the 3rd percentile, has not really changed at all. She did go from 50% to well below third percent by the 2 month age. I did discuss with neurology how much of her head size could be her issues at birth, we don't have her imaging studies so that's hard to know. Mother is 5 foot even and father is 5 foot 9 inches so her mid parental height puts her somewhere around 5 foot 2 inches tall which on her current trajectory is unlikely to occur. We did go ahead and drop once of metabolic labs, she has a normal newborn screen but it would be nice to double check some things.</p> <p>Her CBC and her chemistry panel were normal, her liver enzymes and alkaline phosphatase were normal, her TSH and free T4 were also normal. Her ammonia lactate and organic acids were apparently unable to be drawn since they could not get enough blood. We did have mom increase the formula to 27-calorie formula and then she can do a weight check at her 9 month well visit to see where she is going, if her weight comes up and her height starts responding we can expect hopefully a change in the brain growth. We did discuss most catch-up growth is by 2 years of age if we go to 30-calorie formula, we will need to check chemistries again but we have normal chemistries now so that's good. We will send her to paediatric gastroenterology to get their thoughts, but I do think her reflux was part of her poor caloric intake especially with watery breast milk which was unlikely 20 cal per ounce even when they were adding the supplement. But developmentally she seems to be doing well. Discussed risks and benefits of medications and alternatives and parents understand the risks and wish to continue medications. We did discuss potential side effects of medications and parents agree to proceed with current plan. Mom will continue to check her weight at home on their scale and document an tum into myself or Dr. Benbow.</p> | |

| DATE | FACILITY/ PROVIDER | MEDICAL EVENTS | BATES REF |
|------------|-----------------------|---|-----------------------------|
| | | Follow-up in 1-2 months | |
| 09/11/YYYY | Provider/ Hospital | <p>Pediatric Neurology follow up visit:</p> <p>Patient is doing well. She is 8 months old now. Mother had questions about her EEG. No clinical seizures at this time. Her vision is improving. She is tracking now. She is still having some issues but much better. She is moving all her extremities equally. She likes to put her left arm behind her back. She is equally uses both side equally and often will use the left over the right sometimes. She is transferring objects to both hands. Babbling, mama / dadada, smiling and laughings, she is interested in toys. She is getting 1st steps. She had having difficulty with weight gain. Will be seeing a nutritionist. She continues on Keppra without side effects.</p> <p>Developmental history: She is rolling over, she is not reaching for objects. She is not bringing toys to midline. She is smiling, laugh, cooing. She is moving all side equally. She likes social games. She is not tracking well, no concerns about her hearing. No problems with feeding. Bottle feeds with breast milk. She is in 1st step currently. Vision therapy.</p> <p>Physical examination: Weight 5.92 kg (<1%tile) Height 8.5 cm Head circumference 39.5 cm (<1%tile)</p> <p>Neurologic Examination: Patient was alert Pupils were equal, round and reactive to light and extraocular movements were intact. Kept her head turned to the left as well as gaze but will go to midline and two the right. On motor exam, patient had normal bulk and tone with symmetric, tended to keep the right arm in flexed position, the left arm was moving more. On coordination exam, mild jitteriness noted.</p> <p>Assessment: Baby is a 5 month old female with a diffuse cerebral hypoxic/ischemic injury. There are signs of developmental delay and she tends to have a left gaze preference and does not use the right arm as much as the left arm. She has been seizure free since hospitalization. She has been so far successfully weaned of the Phenobarbital. She is on monotherapy Keppra without side effects. She is currently in the appropriate therapies.</p> <p>Recommendations: 1. Continue Levetiracetam 60 mg thrice daily (30 mg/kg/day) 2. Continue therapies. 3. We have discussed the prognosis, pathophysiology and treatment risk vs benefits in today's visit. 4. Return in about 6 months</p> | Ex 2 000663- Ex 2 000669 |

| DATE | FACILITY/ PROVIDER | MEDICAL EVENTS | BATES REF |
|------------|-----------------------|---|---|
| | | Orders placed as follows: Levetiracetam (Keppra) 100 mg/ml solution. | |
| 09/13/YYYY | Provider/ Hospital | <p>Office Visit for low weight and growth delay:</p> <p>Chief Complaint: New patient for low weight and growth delay. Has significant health issues present since birth. Referred by Dr. Spinelli but sees Neuro at Mercy and other scopes at Cox.</p> <p>New patient to be seen for poor growth, appetite and weight gain. Parent reports only taking approximately 5 oz at each feeding.</p> <p>History of present illness: Per mom, patient has weight gain issues since approximately 3-4 months of age. Previously she was on fortified breastmilk but she stopped breast-feeding and now his feeding 27 kcal Enfamil gentle ease 5-6 ounces every 3-4 hours during the day. Patient will usually sleep from 10 PM to 6 AM without feeding overnight. Her stools are typically every other day, sometimes they are hard other times they are normal. Denies any blood. When she was first fortified she did have some increased spit up which was treated with Zantac and improved. Currently is not having any significant issues with reflux and reportedly takes her bottles well-no choking/gagging/coughing with feeds. His getting baby food once a day "Loves bananas" and does not have any issues with taking solids. Has a history of seizures as neonate secondary to HIE and her last seizure was last December. Last EEG showed some left frontal lobe abnormalities. Today overall not have any acute complaints.</p> <p>Physical examination: Weight 14.52 lb Height 26.25 inch</p> <p>Assessment/plan: 1. Decreased growth (Other lack of expected normal physiological development in childhood) 8-month-old female on 27 kcal per ounce formula, drinking 5-6 ounces every 3-4 hours while awake. Total daily caloric intake with this is approximately 101 kcal/kg/day, which if she is getting this volume should be sufficient for growth. Does not have any overt dysphagia symptoms and feels well from bottle. To date, no underlying syndromic or metabolic diagnosis has been made and while she does have some delayed milestones this would not be unexpected given her history of HIE. Overall, I suspect she is very close to demonstrating some catch-up growth, if not already as her velocity seems to improve lately. Recommended some fortification of her solids using fat/protein-heavy cream, coconut oil, avocado, etc. Her 27 kcal fortified Enfamil I am okay with her now as well-if constipation comes in issue recommend 1-2 ounces undiluted prune/parasites speech to or potentially milk of magnesia</p> | Ex 2 000417- Ex 2 000420, Ex 2 000423- Ex 2 000439 |

| DATE | FACILITY/ PROVIDER | MEDICAL EVENTS | BATES REF |
|------------|-----------------------|--|---|
| | | <p>if symptoms are persistent. No acute changes today other than above, and recommend following up in a couple of months her weight check and reassessment of symptoms. Furthermore, we should have paediatric dietitian on staff here to also assist with dietary plan</p> <p>2. Developmental delay (Unspecified lack of expected normal physiological development in childhood) Likely related to her complications of delivery, is being followed and at this point I do not suspect she has any upper pharyngeal issues with feeds, if concerns arise would recommend swallow study.</p> | |
| 09/27/YYYY | Provider/ Hospital | <p>Office Visit for well child visit:</p> <p>Chief complaint: Here for 9 month well child check.</p> <p>Development Personal Social and Language: Minimal Skills: Regards own hand (by report), Single syllables (by report), Turns toward voice, Expresses/responds to emotions.</p> <p>Fine Motor/Gross Motor: Minimal Skills: Looks for yarn/object, Rakes raisin, Passes cube, Stands, holding on, Pulls to sit, no head lag, Sits without support.</p> <p>Hearing: Head turning with noise.</p> <p>Vision: Observation for blinking, Following with ophthalmology for vision.</p> <p>Physical examination: Weight 5.94 kg Height 27 inch Head circumference 15.25 inch</p> <p>Impression and Plan: Diagnosis Well baby, over 28 days old. Course: Improving.</p> <p>Plan: Immunizations per schedule Continue care with GI for failure to thrive. Continue with neurology for seizure disorder; on stable dose of Keppra. Occupational health working with patient. Continue follow up with Dr. Spinelli to monitor developmental delay.</p> | Ex 2 000395- Ex 2 000397, Ex 2 000398- Ex 2 000404 |
| 11/07/YYYY | Provider/ Hospital | <p>Follow up visit:</p> <p>Chief Complaint: 2 month follow up for weight, growth delay.</p> <p>History of Present Illness: Patient was placed on 27 kcal Enfamil gentle ease and was taking this 5-6 ounces every 3-4 hours at last visit. She has continued on 27 kcal formula and currently is taking 6-6.5 ounces every 3-4 hours. She typically will</p> | Ex 2 000344- Ex 2 000345, Ex 2 000346- Ex 2 000362 |

| DATE | FACILITY/ PROVIDER | MEDICAL EVENTS | BATES REF |
|------------|-----------------------|--|---|
| | | <p>sleep from 10 PM to around 6 AM daily. Stools are still daily to every other day. She manages to soften term with prune juice when needed. She reportedly takes her bottles well-no choking/gagging/coughing. Getting baby food once a day. Has a history of seizure as a neonate secondary to HIE and last but she unfortunately had a recurrence of nighttime seizure on October 18. This consisted of body stiffening, jaw movements, eyes rolling in to her head that lasted 2-3 minutes. Postictal phase 5-10 minutes as well. By report her last EEG showed some left frontal lobe abnormalities. She contacted her neurologist to increase her Keppra to 1.2 ml twice daily.</p> <p>Physical examination: Height 27 in Weight 13.55 lb</p> <p>Assessment/Plan 1. Infant failure to thrive (Failure to thrive (child): 10-month-old female history of seizure disorder, developmental delay and poor weight gain. Has gained less than 10 g per day since last visit and is plateauing in weight. Currently is on 27 kcal formula, 6.5 ounces every 3-4 hours. Mother reports typically 5-5 ½ bottles per day. Utilizing this volume, she would be getting approximately 134 kcal/kg/day to 150 +kcal/kg/day which should be sufficient for weight gain and catch-up. No evidence of malabsorption or excessive emesis.</p> <p>Possibilities for continued poor weight gain would include: 1) Less total caloric intake than mother is reporting either from fortification issues or lower volumes, 2) Subclinical seizure activity and recent overt seizure increasing metabolic visualization or 3) Underlying genetic disorder. At this time, there is no indication of underlying organic GI pathology and discussed with mother substituting 2-3 bottles of PediaSure for 2-3 bottles of 27 kcal formula per day until approximately 12 months of age at which time she can completely switch to PediaSure. Discussed monitoring stool output for worsening constipation on increased caloric density diet. Recommend follow-up with paediatrician for weight checks and routine well-child visits. If no improvement in weight gain velocity may require admission tor observed feeds. Recommend follow up with me in 2 months, sooner if needed or any concerns.</p> | |
| 11/08/YYYY | Provider/ Hospital | <p>Follow-up Visit for developmental re-evaluation:</p> <p>History of Present Illness: Subjective: 10-month-old female here for developmental reevaluation. She was small size with poor artery intake. We first saw her we determine her breastmilk was really not adequate for growth. We did switch her to formula and increase her to a high caloric density formula. She is on 27-calorie formula currently and eating quite a bit, she did see</p> | Ex 2 000364- Ex 2 000365, Ex 2 000366- Ex 2 000372 |

| DATE | FACILITY/ PROVIDER | MEDICAL EVENTS | BATES REF |
|------------|-----------------------|--|---|
| | | <p>gastroenterology and she had gotten up to 14-1/2 pounds. She was gaining weight, they had no reason to continue following her. Mom states she is eating quite a bit, she does like chicken and rice and a number of different foods. She is still using high-calorie formula regularly and sleeping well. She has been more active since the gastroenterology visit in mid September. She did have a well visit and I started her vaccinations. He does have a history of HIE and she did have another seizure since our last visit, they adjusted her Keppra and that seems to be helping. She no longer has any esophageal reflux on the Zantac. She is currently in first steps and getting therapy. She is getting PT speech and OT.</p> <p>Physical exam: Weight: 13.20 lb.</p> <p>Assessment/Plan: 1. Developmental delay (Unspecified lack of expected normal physiological development in childhood: Developmental delay and underweight She did drop to 13.9 pounds from 14.5 but this is pretty normal with increased activity. She is still delayed, she is closer to a 6-8 month-old for many of her developmental level than a 10-month-old. She is in all the required therapies, she is eating better and she is no longer spitting up. At this point other than following her developmental milestones which I think her primary care paediatrician can do, I don't really need to follow up with her again unless her primary care paediatrician and mother feel its worst coming back. At this point, I'm just going to have her continue to do therapy, we did discuss that a lot of catch-up growth is done by 2 years of age. She will be in first steps until she is 3 years old, if mom wants to follow up she can follow-up in about 6 months. Parents agree to proceed with current plan.</p> <p>Follow-up in 6 months or as needed</p> <p>2. Decreased growth (Other lack of expected normal physiological development in childhood)</p> | |
| 12/04/YYYY | Provider/ Hospital | <p>Follow-up Visit:</p> <p>Chief Complaint: 1 month follow up for failure to thrive.</p> <p>History of present illness: Patient was placed on 27 kcal Enfamil gentle ease and was taking this 5-6 ounces every 3-4 hours at last visit. At last visit continued on that 27 kcal formula and was taking 6-6.5 ounces every 3-4 hours. Then and now she will typically will sleep from 10 PM to around 6 AM daily. At last visit she had had a seizure the previous month (October) for which her Keppra was increased to 1.2 ml twice daily, unfortunately she had another seizure</p> | Ex 2 000311- Ex 2 000313, Ex 2 000314- Ex 2 000315, Ex 2 000324- Ex 2 000325 |

| DATE | FACILITY/ PROVIDER | MEDICAL EVENTS | BATES REF |
|------|-----------------------|---|-----------|
| | | <p>in November and her Keppra was increased again-now is 1.5 ml twice daily.</p> <p>At last visit plan was to substitute PediaSure for 2-3 of her bottles per day. Mother states they attempted this, however patient then had issues with constipation and skipping days stooling. Therefore, mother stopped it approximately 1-2 weeks ago. Currently she is back on her 27 kcal Gentlease formula, 7 ounces in the morning, 4-5 ounces in late morning, 7 ounces early afternoon, 7 ounces late afternoon, and 5-7 ounces in the evening. She gets solids twice a day at lunch and dinner. Today does not have any acute complaints. Is feeding well, stooling her normal pattern and has no new symptoms.</p> <p>Physical examination: Height 27 inch Weight 13.68</p> <p>Assessment and plan: 1. Poor weight gain in infant (Failure to thrive) 11-month-old female with history of seizure disorder, developmental delay and poor weight gain. Continues to have slow weight gain/plateauing. Last visit discussed increasing her calories with PediaSure, unfortunately shows unable to tolerate this due to constipating side effects and continues on her old formula of 27 kcal. Her current formula intake alone should provide 130 kcal/kg/day which should be sufficient for growth, especially with her added solids. Suspect with her increase in seizure activity this may be burning more calories and discussed with mother closely monitoring for any signs of seizure activity- especially at night when she is not monitored.</p> <p>Possibilities for continued poor weight gain would include 1) Less total caloric intake than mother is reporting either from fortification issues or lower volumes. 2) Sub clinical seizure activity and recent overt seizure increasing metabolic visualization or 3) Underlying genetic disorder. At this time, there is no indication of underlying organic GI pathology and will attempt to reintroduce PediaSure into her diet, first with substituting first morning bottle with PediaSure and adding lactulose, 1 teaspoon to 1 tablespoon per day to help loosen her stools. If tolerates this well, with then subsequent to her last quality with PediaSure as well. Also discussed fortifying her solids with heavy whipping cream and healthy fat/oils.</p> <p>Recommend follow-up with paediatrician for weight check at 12 month well baby and routine well-child visits. As discussed previously if no improvement in weight gain velocity may require admission for observed feeds. At this point do not feel NG or G-tube indicated but will continue to monitor.</p> | |

Patient 1
Patient 2

DOB: MM/DD/YYYY
DOB: MM/DD/YYYY

| DATE | FACILITY/ PROVIDER | MEDICAL EVENTS | BATES REF |
|------------|-----------------------|---|---|
| | | Follow up in 2 months. | |
| 12/05/YYYY | Provider/ Hospital | <p>Office Visit for well child visit:</p> <p>Interval History/Parent & Child Concerns: Here for continued vaccination and weight check. Reports she has had some additional seizures and had medications increased. Has been working with peds GI to increase weight. Has upcoming cardiology appt.</p> <p>Development Personal Social and Language: Minimal Skills: Regards own hand (by report), Single syllables (by report), Imitates speech sounds, Expresses/responds to emotions.</p> <p>Fine Motor/Gross Motor: Minimal Skills: Rakes raisin, Passes cube, Stands, holding on, Sits without support.</p> <p>Hearing: Parental perception of hearing normal.</p> <p>Vision: Improving vision per mother. Last vision therapy last month another one next month. Field of vision expanding.</p> <p>Physical examination: Weight 6.2 kg Height 27.5 in Head circumference 16 in</p> <p>Impression and Plan: Diagnosis: Developmental delay. Failure to thrive in infant. Seizure disorder.</p> <p>Plan: Immunizations per schedule, Mother requests continuing catch up vaccinations. Will give today. Continue care with peds GI. Reviewed developmental peds note and will follow up in 6 months. Continue therapy as scheduled and follow up with eye doctor. She is to include heavy whipping cream to foods in order to increase calories. Consideration of admission for observation of feeds if no improvement. Return for 12 month well child check.</p> | Ex 2 000280- Ex 2 000282, Ex 2 000283- Ex 2 000309 |
| 12/11/YYYY | Provider/ Hospital | <p>Office Visit for eye misalignment:</p> <p>Patient presents with mom. She states that she feels like she is looking at her more and making eye contact with her more. She states that she does still notice her eyes drifting out occasionally.</p> <p>Assessment and Plan: 1. Exotropia, intermittent Currently well controlled when fixing on near objects</p> <p>Plan:</p> | Ex 8 000046- Ex 8 000054, Ex 8 000041- Ex 8 000045, Ex 8 000115- Ex 8 000118, Ex 8 000125- Ex 8 000129 |

Patient 1
Patient 2

DOB: MM/DD/YYYY
DOB: MM/DD/YYYY

| DATE | FACILITY/ PROVIDER | MEDICAL EVENTS | BATES REF |
|------------|-----------------------|---|---|
| | | <p>Observe Recheck in 6 months</p> <p>2. Ocular motor apraxia syndrome Less characteristics of ocular motor apraxia seen on this visit but still has occasional compensatory head movement when following objects.</p> <p>Return in about 6 months</p> | |
| 12/28/YYYY | Provider/ Hospital | <p>Cardiology follow-up Visit:</p> <p>Patient has no interval history for cyanosis, syncope or loss of consciousness, dyspnea on exertion or shortness of breath. There is no history for easy fatigability or failure to thrive. No history for asthma or wheezing. She has had no serious acute illnesses or hospitalizations.</p> <p>Physical examination: Musculoskeletal: Normal tone. Left extremity motor weakness. Moves all extremities appropriately.</p> <p>Echocardiogram: Very small muscular VSD. Normal LV function and size.</p> <p>Impression: Ventricular Septal Defect</p> <p>Plan and Recommendation:</p> <ol style="list-style-type: none"> 1. Echocardiogram - Focused in 1 year 2. No cardiovascular restrictions necessary 3. Follow-up visit in 1 year. (Echocardiogram) 4. Subacute bacterial endocarditis prophylaxis is not required for this condition. 5. Dietary recommendations include: regular. 6. She appears well and her muscular VSD is very small by echo. It has a high likelihood of spontaneously closing. <p>Follow up in 2 years.</p> | <p>Ex 2 000056- Ex 2 000057, Ex 6 000008- Ex 6 000009</p> |
| 01/03/YYYY | Provider/ Hospital | <p>Office Visit for Well child visit:</p> <p>Development Personal Social and Language: Minimal Skills: Plays pat-a-cake (by report), Dada, Mama, non-specific (by report), Exhibits range of emotions.</p> <p>Fine Motor/Gross Motor: Minimal Skills: Takes two cubes, Bangs 2 cubes in hands (by report).</p> <p>Hearing: Parental perception of hearing normal.</p> <p>Vision: Still has weakening of her eye muscles. Seen by the eye doctor since last visit. She is now able to sit without assistance. She is laughing and enjoys pick a boo. She is clapping her hands and likes to play pat a cake. She enjoys holding her rattle to make noise. She will say mama and dada but not specifically. Mother notes she does have trouble on focusing on things far away but she can hear when her mother enters a room. She will</p> | <p>Ex 2 000274- Ex 2 000276, Ex 2 000277- Ex 2 000278</p> |

Patient 1
Patient 2

DOB: MM/DD/YYYY
DOB: MM/DD/YYYY

| DATE | FACILITY/ PROVIDER | MEDICAL EVENTS | BATES REF |
|------------|-----------------------|---|---|
| | | <p>track some objects closer to her.</p> <p>Physical examination: Weight 6.45 kg Height 27.5 in</p> <p>Impression and Plan Diagnosis Encounter for well child visit at 12 months of age. Course: Improving.</p> <p>Plan: Continue with current eating plan. Continue home exercises and activities per OT. While still delayed she has had some improvement in developmental milestones since her last visit. Mother getting patient caught up on immunizations. Return in one month for 6 month shots.</p> | |
| 01/08/YYYY | Provider/ Hospital | <p>Follow-up visit for weight check:</p> <p>History of Present Illness: Patient is a 12-month-old female, accompanied by mother and father, here for follow-up paediatric GI visit for history of failure to thrive. Today does not have any acute complaints. Is feeding well and has no new symptoms.</p> <p>She has an early intervention meeting later in January and reportedly her feeding team/speech pathologist would like modified barium swallow to help guide future diet interventions.</p> <p>Physical examination: Weight 14.17 lb</p> <p>Assessment and plan: 1. Poor weight gain in infant Currently is tracking below the curve but is gaining steadily. Last visit discussed increasing her calories with PediaSure, even one half to one bottle per day would be beneficial. She has done reasonably well with giving this on a regular basis but is not a daily occurrence. Lactulose is not controlling her constipation symptoms completely and recommend switching from lactulose to Miralax, initially a one quarter capful, titrated to daily soft stools. Continue current diet plan, heavy whipping cream, coconut oil, and can also start to supplement eggs, ground meats (especially mixed with her mashed potatoes), nut butters, etc.</p> <p>Will order swallow study to assist with early intervention planning. Will notify mother of results.</p> <p>No evidence of metabolic derangements. No evidence of GERD or vomiting. No evidence of mal-absorption.</p> | Ex 2 000253- Ex 2 000255, Ex 2 000228- Ex 2 000230, Ex 2 000256- Ex 2 000272 |

Patient 1
Patient 2

DOB: MM/DD/YYYY
DOB: MM/DD/YYYY

| DATE | FACILITY/ PROVIDER | MEDICAL EVENTS | BATES REF |
|------------|-----------------------|---|---|
| | | <p>Recommend follow-up with paediatrician as they have previously planned, can follow-up with me in approximately 2 months, sooner if needed or any concerns.</p> <p>Ordered: FL Modified Barium Swallow and Video</p> <p>2. Developmental delay (Unspecified lack of expected normal physiological development in Childhood): No overt seizure activity since last visit. Still delayed, no unifying diagnosis. Small breast buds noted bilaterally today, we'll follow up on this at next visit.</p> | |
| 02/04/YYYY | Provider/ Hospital | <p>Modified Barium Swallow and Video:</p> <p>Reason For Exam: Poor weight gain in infant, Developmental delay.</p> <p>Technique and findings: Fluoroscopic evaluation of swallowing mechanism was performed in conjunction with the department of speech pathology. Patient was given thin, thickened, and pudding consistency barium. Please see separate report from speech pathologist for discussion of swallowing mechanism. No aspiration was visualized. Fluoroscopic exposure was 2 minutes. Single lateral projection of the head and neck submitted.</p> <p>Impression: Modified barium swallow as described above. Please refer to the separate report from the speech pathologist for further details.</p> | Ex 2 000251 |
| 02/04/YYYY | Provider/ Hospital | <p>Speech Therapy Assessment:</p> <p>Patient presents with mildly impaired oral motor strength noted specifically with movement of a thicker bolus such as honey & pureed. Decreased lingual agility for movement of the bolus evident. Occasional anterior leakage & residue remaining after the swallow. She was able to close her lips of the spoon for removal of the bolus. She demonstrated adequate latching on with the Dr. Brown bottle/nipple combination. Sucking strength was adequate as well with consistent nutritive sucking bursts. No obvious delays with initiation of the pharyngeal swallow reflex were evident. No episodes of laryngeal penetration or tracheal aspiration occurred even with varying bolus sizes & consecutive swallows. No obvious significant superior movement of the bolus was observed. No coughing, choking, gagging or vomiting occurred.</p> <p>Impression: Mild oral dysphagia Primary swallowing deficits: Reduced oral motor control Recommendation: Begin/continue oral diet</p> <p>Results/recommendations reviewed with mom who wants to continue with speech therapy services through First Steps.</p> | Ex 2 000232- Ex 2 000235, Ex 2 000236- Ex 2 000250 |

Patient 1
Patient 2

DOB: MM/DD/YYYY
DOB: MM/DD/YYYY

| DATE | FACILITY/ PROVIDER | MEDICAL EVENTS | BATES REF |
|------------|-----------------------|--|-----------------------------|
| | | Recommend that patient continue with the recommended diet by her physician. | |
| 02/20/YYYY | Provider/ Hospital | Individualized Family Service Plan – Occupational therapy initial progress notes: Progress summary: This was the initial visit patient. She was awake and alert when therapist arrived and was just finishing a bottle. She had minimal leakage from the corner of her mouth but was also sleeping and falling asleep. Patient has minimal head control but mom reports she is doing tummy time daily for 2-3 minutes at a time. Patient turns her head to both sides but mom thinks she likes her left, provided positioning ideas to encourage turning to both sides. Patient also is sensitive to her feet, talked about doing firm massage on her feet to decreased sensitivity. Also encouraged mom to use feet hers with a variety of textures as appropriate and also vibration to help with possible oral aversion as well due to the tubes in her mouth from the ICU stay. She verbalized understanding | Ex 5 000115- Ex 5 000116 |
| 03/13/YYYY | Provider/ Hospital | Neurology Visit for seizures: Patient is doing overall great. She had another episode last week. She is having these rare. The last one was in November. She leans back and stiff. Lasts about a minute and a half. No side effects of the Keppra. She still has therapy. She is getting OT/SLT/Vision therapy. She is rolling not much. She raise up to sit up. They are working on getting her a gait trainer. She does have a jumparoo. Developmental History: she is rolling over, she is not reaching for objects. She is not bringing toys to midline. She is smiling, laugh, cooing. She is moving all side equally. She likes social games. She is not tracking well, no concerns about her hearing. Bottle feeds with breast milk. She is in 1st step currently. Vision therapy. Physical examination: Weight 6.93 kg (<1%tile) Height 28.25 in (2%tile) Head circumference 42 (<1%tile) Neurologic Examination: Patient was alert. Pupils were equal, round and reactive to light and extraocular movements were intact. Did not make good eye contact, interested in looking at the ceiling and the lights. Facial muscles appeared symmetric. On motor exam, patient had normal bulk and tone with symmetric, the left arm was moving more. No vertical slip through, good horizontal position, would bare weight on legs and bounce, no parachute. | Ex 2 000049- Ex 2 000055 |

| DATE | FACILITY/ PROVIDER | MEDICAL EVENTS | BATES REF |
|------------|-----------------------|--|---|
| | | <p>Assessment: Baby is a 14 month old female with a diffuse cerebral hypoxic/ischemic injury. She has infantile cerebral palsy. I am concerned she has cortical visual impairment. She has global developmental delays. She has probable focal onset symptomatic epilepsy with impairment of consciousness. She has rare seizures. Her last seizure was about a week ago. EEG shows left hemisphere epileptiform discharges. She is on monotherapy Keppra without side effects. She is currently in the appropriate therapies.</p> <p>Recommendations. 1. Levetiracetam increase to 180 mg twice daily 2. EEG if continues to have seizures and MRI (2yo) 3. Continue therapies 4. Spent time discussing spine and hip development 5. Spent time discussing diagnosis of CP and treatment plans 6. We have discussed the prognosis, pathophysiology and treatment risk vs benefits in today's visit. 7. Return in about 6 months</p> | |
| 03/26/YYYY | Provider/ Hospital | <p>Office Visit for well child visit:</p> <p>Developmental Milestones: GP/delayed - First Steps involved.</p> <p>Physical examination: Weight 7.002 kg (<1%tile) Height 28.35 inch (2%tile) Head circumference 41.5 cm (<1%tile) Extremities: Extremities normal, atraumatic, no cyanosis or edema, moves all extremities, normal strength, increased tone.</p> <p>Assessment: Normal growth and development for gestational age.</p> <p>Plan: 1. Age appropriate Baby Your Baby Pamphlets provided. Additional anticipatory guidance given including next stages of development 2. Screening tests: None indicated 3. Immunizations today: Pediarix, Hib, Prevnar, MMR. Appropriate VIS given at today's visit. No history of previous adverse reactions to immunizations. 4. Return to clinic in 3 months for next well child visit</p> | Ex 7 000008- Ex 7 000011, Ex 7 000012- Ex 7 000016, Ex 7 000099- Ex 7 000101 |
| 04/01/YYYY | Provider/ Hospital | <p>Follow-up Visit:</p> <p>History of Present Illness: Baby is a 15-month-old female, accompanied by mother, here for follow-up paediatric GI visit for history of failure to thrive. Has a history of underlying seizure disorder and has had several issues with breakthrough</p> | Ex 2 000181- Ex 2 000186, Ex 2 000187- Ex 2 000201 |

| DATE | FACILITY/ PROVIDER | MEDICAL EVENTS | BATES REF |
|------------|-----------------------|---|---|
| | | <p>seizures in the past while on Keppra, most recently was just prior to follow-up visit with paediatric neurologist, and her Keppra was increased after this seizure from 1.5 mL twice a day to 1.8 ml twice a day. If seizures recur again, plan is to perform EEG and MRI, which currently are scheduled for when she turns 2. Continues to have no issues with reflux, and feeds well without choking/gagging/coughing. Lactulose does seem to improve her stool consistency, though they still are sometimes rather firm. No other GI symptoms or acute concerns today. No new symptoms.</p> <p>Physical examination: Weight 15.4 lb Height 29.05 in</p> <p>Assessment/Plan 1. Decreased growth (Other lack of expected normal physiological development in childhood) 15 month female with history of seizure disorder, developmental delay and poor weight gain, tracking below growth curve but is gaining steadily. Given her demonstrated adequate weight gain over the previous 6+ months, recommend continuing her current diet plan and constipation management Continue Miralax, titrated to daily soft stools.</p> <p>2. Developmental delay (Unspecified lack of expected normal physiological development in childhood) Breakthrough seizure after last visit, subsequent increasing Her dosing. EEG and MRI planned if another seizure occurs prior to her two-year follow-up with paediatric neurology. Still delayed, no unifying diagnosis.</p> <p>3. Breast buds (Precocious puberty) Small breast buds noted bilaterally, persistent from previous visit. Can follow up with PCP regarding this, or can reassess in 3-4 months at her next follow-up visit and discuss potential options for evaluation.</p> | |
| 05/28/YYYY | Provider/ Hospital | <p>ER visit for cough</p> <p><i>*Reviewer's comment: Direct report for ER visit on this day is not available for review. Only brief visit summary is available.</i></p> | Ex 2 000164- Ex 2 000172, Ex 2 000175- Ex 2 000178 |
| 07/01/YYYY | Provider/ Hospital | <p>Follow-up Visit for well child exam:</p> <p>Receiving OT, speech and vision.</p> <p>Assessment: Normal growth and development for gestational age.</p> <p>Physical examination: Weight 7.275 kg (<1%tile) Height 29.21 in (1%tile) Head circumference 41.7 cm (<1%tile)</p> | Ex 7 000031- Ex 7 000033, Ex 7 000024- Ex 7 000030, Ex 7 000034- Ex 7 000040, Ex 7 000102- Ex 7 000107 |

Patient 1
Patient 2

DOB: MM/DD/YYYY
DOB: MM/DD/YYYY

| DATE | FACILITY/ PROVIDER | MEDICAL EVENTS | BATES REF |
|------------|-----------------------|--|---|
| | | <p>Extremities: Extremities normal, atraumatic, no cyanosis or edema, moves all extremities, normal strength, increased tone.</p> <p>Assessment: Normal growth and development for gestational age.</p> <p>Plan: 1. Age appropriate Baby Your Baby Pamphlets provided. Additional anticipatory guidance given including next stages of development 2. Screening tests: MCHAT evaluation completed and is abnormal 3. Immunizations today: Hep A, varicella, prevnar, Hib and DTaP. Appropriate VIS given at today's visit. 4. Return to clinic in 6 months for next well child visit.</p> | |
| 07/08/YYYY | Provider/ Hospital | <p>Individualized Family Service Plan – 6 month review:</p> <p>Present level of development and daily routine: Wake-up: Patient sleeps in a crib in her parent's room. She will wake up between 6 and 7 AM. Her parents know when she is waking up because she will start making noises. Patient is starting to stay awake more during the day but still sleeps most of the day.</p> <p>Mealtime: Developmental areas: Adaptive, cognitive Patient takes a 7 oz bottle every 3 hours. She is eating baby food and loves to eat mashed potatoes. Patient also has one can of PediaSure a day. She will try to put puffs in her mouth but has not been to get them in yet.</p> <p>Play: Developmental areas: Physical, social/emotional, communication Patient will crawl by moving legs but not moving arms yet. She will interact with her family members by smiling and laugh out loud. Patient is babbling and can say "Dadda" and "Momma" but does not say it to her parents. Patient will sit with support. She will clap and pick toys up with her hands.</p> <p>Bedtime/naps: Developmental areas: Adaptive Patient takes 30 to 35 mins naps. She does not like to take a nap. Kelsey will rock her until she falls asleep and will put on some music for her. Patient sleeps all night.</p> | Ex 5 000078- Ex 5 000085 |
| 07/15/YYYY | Provider/ Hospital | <p>Follow-up Visit:</p> <p>History of Present Illness Baby is a 18-month-old female, accompanied by mother, here for follow-up paediatric GI visit for history of failure to thrive. Since last visit, did</p> | Ex 2 000140- Ex 2 000142, Ex 2 000143- Ex 2 000157 |

| DATE | FACILITY/ PROVIDER | MEDICAL EVENTS | BATES REF |
|------------|-----------------------|--|---|
| | | <p>have significant sinusitis/illness for most of the month of June per mom which she has only recently over the past couple of weeks begun to recover from in regards to caloric intake. Continues to have no issues with reflux, and feeds well without choking/gagging/coughing. Taking 2 cans of boost or PediaSure daily along with normal solids. Had one episode of blood in stool 3-4 days ago after a large stool event, none since then.</p> <p>Physical examination: Weight 16.31 lb Height 29. 5 in</p> <p>Assessment/Plan 1. Decreased growth (Other lack of expected normal physiological development in childhood) 18 month female with history of seizure disorder, developmental delay and poor weight gain, tracking below growth curve but is gaining steadily. Given her demonstrated adequate weight gain over the previous several months recommend continuing her current diet plan and constipation management. Continue Miralax or lactulose titrated to daily soft stools. Strongly consider genetics consult depending on her continued developmental trajectory and physical findings, has paediatric ophthalmology visit pending. Samples of PediaSure and boost given.</p> <p>2. Developmental delay (Unspecified lack of expected normal physiological development in childhood) Continues to have intermittent breakthrough seizures, most recently in April with subsequent dose escalation of Keppra. EEG and MRI was reportedly previously planned, if another seizure occurs prior to her two-year follow-up with paediatric neurology, but this was not obtained after last seizure. Still significant developmental delay, no unifying diagnosis.</p> <p>3. Breast buds (Precocious puberty) Breast positive now been present for past couple of visits, given her age likely is benign but with other issues currently going on in regards to ophthalmology/developmental/seizures, recommend paediatric endocrinology consultation to evaluate</p> | |
| 07/16/YYYY | Provider/ Hospital | <p>Follow-up Visit:</p> <p>Baby is a 18 month old female brought by mother presenting with request for referral to Peds Endocrinology. Peds GI noted breast budding and referred, but Insurance requires PCP referral.</p> <p>Physical examination: Weight 7.258 kg Height 29.33 in Breast: Normal bilaterally, suggestion of palpable buds, left > right</p> <p>Assessment:</p> | <p>Ex 7 000051- Ex 7 000053, Ex 7 000044- Ex 7 000050, Ex 7 000054- Ex 7 000062</p> |

Patient 1
Patient 2

DOB: MM/DD/YYYY
DOB: MM/DD/YYYY

| DATE | FACILITY/ PROVIDER | MEDICAL EVENTS | BATES REF |
|------------|-----------------------|---|---|
| | | <p>1. Infantile breast hypertrophy 2. Abrasion of sclera of left eye, initial encounter</p> <p>Plan: Discussed normal breast tissue by my exam. Secondary to maternal concern and request of Peds GI, refer.</p> | |
| 07/17/YYYY | Provider/ Hospital | <p>Follow-up Visit:</p> <p>Patient's mother reports that she can tell that patient is still having loss of vision superior and inferior temporal in the right eye. She also reports that the right eye will "wander". Patient mother reports that she feels like she can see a "haze" over the right eye at times as well. This "haze" is not always present.</p> <p>Patients grandmother watches patient during the day and will notice that patient will try to look at something in the distance, but will not be able to find what she is trying to look for. She will also try to show patient the cat and the patient seems to not be able to look at where the cat is.</p> <p>Assessment and Plan: 1. Cortical visual impairment Stable ocular structures. Will monitor.</p> <p>2. Exotropia, intermittent Still variable exotropia. Moderately well controlled.</p> <p>3. Hyperopia, bilateral No treatment currently needed.</p> <p>Return in about 6 months (around 1/17/YYYY).</p> | <p>Ex 8 000079- Ex 8 000086, Ex 8 000072- Ex 8 000078, Ex 8 000087- Ex 8 000090, Ex 8 000130- Ex 8 000133</p> |
| 08/15/YYYY | Provider/ Hospital | <p>Office Visit for breast budding:</p> <p>19 month previously term AGA female presents with mother and grandmother for initial endocrinology evaluation to discuss development of breast buds. Breast development first noticed 04/YYYY at pediatric GI visit with Dr. J Hefner.</p> <p>Baby has a history of likely perinatal stroke and subsequent HIE with cerebral palsy, seizure disorder and developmental delay. She has been on Keppra for seizures. MRI at birth with ischemic changes in the posterior aspect of her brain. No known pituitary compromise. She is followed by Mercy pediatric neurology - Dr. Collins and repeat MRI is anticipated 09/YYYY.</p> <p>Physical examination: Weight 16.45 lb Height 30.0 in Pubertal Assessment: Breast bud left directly under areola - SMR2, right</p> | <p>Ex 2 000027- Ex 2 000028, Ex 2 000029- Ex 2 000046</p> |

| DATE | FACILITY/ PROVIDER | MEDICAL EVENTS | BATES REF |
|------------|-----------------------|--|-----------------------------|
| | | <p>smaller, still SMR</p> <p>Assessment/Plan: 1. Premature thelarche (Other disorders of puberty) Benign, isolated premature thelarche. No evidence of true, precocious puberty without pubic or axillary hair. No increased linear growth. With history of HIE and intracranial abnormalities, precocious puberty risk is increased, but I do not see evidence of that at this time. Recommend follow up in 6 months to monitor for progression. May consider BA at that time if progression. Also requested copy of MRI results when completed through Mercy to verify pituitary is normal.</p> <p>Discussed: Pubertal norms and variations. Pubertal pace and progression. Bone age evaluation. Age and developmental appropriate guidance. Pubertal evaluation and potential treatment.</p> <p>2. Developmental delay (Unspecified lack of expected normal physiological development in childhood)</p> | |
| 09/06/YYYY | Provider/ Hospital | <p>Individualized Family Service Plan – Physical therapy Final progress notes:</p> <p>Progress summary: Patient was eating soup for lunch when PT and OT arrived. She was taking large bites from a baby spoon and did well with eating today. Patient was very fussy and mad during session today. Mom reports she woke up at 10:30 AM yesterday morning and didn't go to bed until 11:00 PM with no nap during the day. Patient worked on standing today with her chair placed behind her. She continues to require max assist to stand and maintain her balance. She was very resistant to this and cried immediately when placed in standing. She demonstrates decreased static and dynamic balance and stability with standing and walking. Without support, patient immediately falls backwards to her bottom. During walking, patient demonstrates knee hyperextension bilaterally, and demonstrates decreased neuromuscular control of her legs. PT and OT provided hip support while attempting to walk with a push toy today and patient continues to be hesitant to take independent steps. Mom reports they are using her stander 3-5 times per week and she continues to only tolerate around 20 minutes each attempt. PT and OT have recommended a re-evaluation with orthotist. PT believes patient would benefit from additional support at her ankles to help improve her stability and balance with walking and standing, along with preventing knee hyperextension. PT will continue to work on strengthening activities.</p> | Ex 5 000091 |
| 09/25/YYYY | Provider/ Hospital | <p>Individualized Family Service Plan – Occupational therapy Final progress notes:</p> <p>Date of service: 09/25/YYYY, 09/20/YYYY, 09/11/YYYY, 09/06/YYYY</p> | Ex 5 000091- Ex 5 000092 |

Patient 1
Patient 2

DOB: MM/DD/YYYY
DOB: MM/DD/YYYY

| DATE | FACILITY/ PROVIDER | MEDICAL EVENTS | BATES REF |
|------------|-----------------------|--|---|
| | | Progress summary: Activities continue to focus on motor skills and parent education. Morn has been working to establish a sleep schedule with patient but it has not gone well because patient has been taking extremely late naps lately. Discussed with mom, a possible schedule and came up with something that would work for the family. Suggested that mom write it on a piece of paper and hang it up for everyone to see and as a constant reminder of what they're working toward. ST emphasized importance of sleeping schedule as it relates to a meal schedule and increasing calories for weight gain. Mom verbalized understanding. Patient continues to wear her new orthotics and is standing with more tolerance but she will still voice her complaints about it. She needs mod-max assist for standing and not leaning too far forward or backward. Mom reports she is using the stander more often now since she isn't wanting to stand as much in the floor. | |
| 09/25/YYYY | Provider/ Hospital | Individualized Family Service Plan – Speech Language pathologist Final progress notes: Date of service: 09/25/YYYY, 09/18/YYYY Progress summary: Patient is starting to tolerate therapy a little more. She is tolerating standing with her new orthotics more each session. Mom intends to start a new sleep schedule in the near future to help patient establish a better schedule. The therapist also continues to help mom with ideas for weight gain, such as adding heavy cream to her bottles, adding a third solid food meal, and adding a cup of whole milk at bedtime. | Ex 5 000090- Ex 5 000091 |
| 10/01/YYYY | Provider/ Hospital | Office Visit: Patient is a 21 month old female brought by mother presenting with refusal to support body weight on legs for several days. Previously "pulling up". No fever, redness, swelling noted. No illness. Otherwise at baseline for behavior. Physical examination: Extremities: FROM, normal muscle strength of bilateral LE lying on back; will not support weight on legs Assessment: Impaired weight bearing Plan: X-ray of femur and tibia/fubula ordered X-rays read as normal. Discussed possible post viral arthralgia/myalgia. Monitor and treat symptomatically for fussiness or pain. Return to clinic as needed for fever, rash, swelling or other concern. Discussed with OT/PT on Friday for their assessment about change. | Ex 7 000069- Ex 7 000071, Ex 7 000063- Ex 7 000069, Ex 7 000071- Ex 7 000082, Ex 7 000084- Ex 7 000098 |
| 10/01/YYYY | Provider/ Hospital | X-ray of femur: Reason for exam: Impaired weight bearing | Ex 7 000082- Ex 7 000083 |

| DATE | FACILITY/ PROVIDER | MEDICAL EVENTS | BATES REF |
|------------|-----------------------|--|---|
| | | Impression: Unremarkable exam | |
| 10/16/YYYY | Provider/ Hospital | Individualized Family Service Plan – Dietician Final progress notes: Progress summary: Weight today on RD scale 17/9 oz; a gain from last month of 10 oz. Continues to drink about 16 oz of Pediasure each day. Mom has started to blend up more foods from the table that the family is eating and has seen an increase in overall volume intake by patient. Reviewed ways to make the texture acceptable as needed and encouraged her to still add calories with the mix-ins. Discussed the need to add in a 3rd solid food feeding each day rather than just 2. | Ex 5 000090 |
| 10/21/YYYY | Provider/ Hospital | Follow up visit: Chief Complaint: 3 month Check-up. History of Present Illness: Baby is a 21 month-old female, accompanied by mother, here for follow-up paediatric GI visit for continued management of poor weight gain, constipation, underlying seizure disorder and developmental delay. She continues with speech therapy, physical therapy, occupational therapy, etc. over the past several months, mother has been able to make steady improvements in her oral intake and she now takes 2 cans of PediaSure per day in addition to solids- will eat a variety of table foods that mother blenderizes to pureed consistency-usually whenever the family is eating. In addition, she has noticed that she really likes broccoli cheese soup, and she will make this been extremely helpful in helping to stabilize her during mealtimes and avoiding involuntary movements and other rocking behaviors from interfering with meals. Stools have become somewhat worse in regards to constipation, and she struggles with lactulose/Miralax to find a good balance that keeps her going on a daily basis. Unfortunately, her seizures have continued to breakthrough on her medication regimen, most recently requiring Diastal at home. This episode was different than her previous seizures, with her waking during sleep, arching her back, her eyes rolling into her head, and this lasting over 3 minutes which was parents triggered to use Diastat. She was subsequently increased on her Keppra to 2.4 ml twice daily. During previous visits have been increased from 2.1 ml twice daily. This has been a steady trend over the past 6-9 months. Still sleeping normally. No current EEG scheduled. Next planned imaging with MRI at approximately 2 years of age. Physical examination: Height 30.5 in Weight 17.16 lbs Weight today 7.8kg, up from 7.41kg last visit, which was up from 7.0 kg. Previous weights to that 6.44kg and 6.22 kg. Z scores steady. Continues to track below curves for length and weight. Length increased. Musculoskeletal: Moves all extremities equally. Prefers left shoulder posteriorly rotated and left arm behind back | Ex 2 000003- Ex 2 000005, Ex 2 000006- Ex 2 000025 |

| DATE | FACILITY/ PROVIDER | MEDICAL EVENTS | BATES REF |
|-------------------------------|-----------------------|---|-------------|
| | | <p>Neuro: Poor truncal tone, some early scissoring of lower extremities Skin: Warm and dry. No rash or suspicious lesions noted. Small breast buds persistent from previous exam.</p> <p>Assessment/Plan: 1. Decreased growth (Other lack of expected normal physiological development in childhood)</p> <p>21 month old female with history of seizure disorder, developmental delay and poor weight gain, tracking below growth curve but is gaining steadily. Given her demonstrated adequate weight gain over the previous several months recommend continuing her current diet plan- though today did give some samples of PediaSure peptide to see if this decreases some of her need for constipation management medications. Recommend continuing Miralax or lactulose, also discussed potentially adding milk of magnesia, 510 ml daily to see if this helps her stool output as well. no formal genetic consult yet. Samples of boost kid essentials, PediaSure peptide, Peptamen Junior given.</p> <p>2. Developmental delay (Unspecified lack of expected normal physiological development in childhood): Continues to have intermittent breakthrough seizures, most recently last month with subsequent dose escalation of Keppra. This has been a regular occurrence over the past 6-9 months, and she has not seen neurology in person. Previous plan was to repeat EEG.</p> | |
| 10/28/YYYY | Provider/ Hospital | <p>Individualized Family Service Plan – Visual impairment Final progress notes:</p> <p>Progress summary: Patient has had some medical issues and the family is considering taking her to St Louis children's hospital. She was reaching for things she saw even at a couple feet. She was noticing things on the television at 8 feet. She found a lighted halloween torch at 4 feet without any auditory cues. She found her piano even when it was located above the normal locations.</p> | Ex 5 000090 |
| 01/11/YYYY - 10/28/YYYY | Provider/ Hospital | <p>Other related records:</p> <p>Assessment (Bates Ref: Ex 2 000850, Ex 2 000833, Ex 5 000004-Ex 5 000005, Ex 5 000047-Ex 5 000077, Ex 2 000660-Ex 2 000662, Ex 2 000811, Ex 2 000775, Ex 8 000018-Ex 8 000023, Ex 5 000028, Ex 2 000621, Ex 2 000629, Ex 2 000631- Ex 2 000633, Ex 2 000607- Ex 2 000618, Ex 2 000107- Ex 2 000122, Ex 8 000035- Ex 8 000040, Ex 2 000578- Ex 2 000579, Ex 2 000130- Ex 2 000133, Ex 2 000136- Ex 2 000138, Ex 2 000540, Ex 2 000440, Ex 2 000442, Ex 2 000448, Ex 2 000470- Ex 2 000471, Ex 2 000527- Ex 2 000548, Ex 2 000421- Ex 2 000422, Ex 5 000046, Ex 2 000373- Ex 2 000391, Ex 2 000332- Ex 2 000342, Ex 2 000310, Ex 2 000318-Ex 2 000323, Ex 2 000326- Ex 2 000331, Ex 5 000087- Ex 5 000089, Ex 5 000143, Ex 2 000202- Ex 2 000214, Ex 2 000219, Ex 7 000002- Ex 7 000007, Ex 2 000160, Ex 2</p> | |

Patient 1
Patient 2

DOB: MM/DD/YYYY
DOB: MM/DD/YYYY

| DATE | FACILITY/ PROVIDER | MEDICAL EVENTS | BATES REF |
|------|-----------------------|--|-----------|
| | | 000163, Ex 2 000139, Ex 2 000047, Ex 2 000123, Ex 2 000709- Ex 2 000710, Ex 5 000044, Ex 4 000210, Ex 2 000637 Correspondence (Bates Ref: Ex 5 000003, Ex 5 000020, Ex 5 000037, Ex 5 000045, Ex 5 000086, Ex 2 000077, Ex 2 000075, Ex 2 000066- Ex 2 000067) E-mail Conversation (Bates Ref: Ex 5 000034- Ex 5 000036, Ex 5 000131- Ex 5 000133) Labs (Bates Ref: Ex 2 000646- Ex 2 000658, Ex 2 000630, Ex 2 000449- Ex 2 000456) Medication Sheets (Bates Ref: Ex 2 000134- Ex 2 000135, Ex 2 000215- Ex 2 000218) Nursing Notes/Records (Bates Ref: Ex 3 000647, Ex 5 000090- Ex 5 000116) Office Visit for medication refill (Bates Ref: Ex 8 000055-Ex 8 000071, Ex 8 000091-Ex 8 000106, Ex 3 000506-Ex 3 000546, Ex 3 000548-Ex 3 000564) Orders (Bates Ref: Ex 2 000457-Ex 2 000469, Ex 5 000130, Ex 5 000134- Ex 5 000135) Patient Education (Bates Ref: Ex 2 000856-Ex 2 000869, Ex 2 000871-Ex 2 000886, Ex 2 000573-Ex 2 000575) Referral Report (Bates Ref: Ex 5 000006- Ex 5 000007, Ex 5 000033, Ex 2 000080, Ex 2 000076, Ex 2 000078, Ex 2 000072, Ex 2 000106) Telephone Conversation (Bates Ref: Ex 2 000086-Ex 2 000102, Ex 2 000576-Ex 2 000577, Ex 2 000523-Ex 2 000526, Ex 2 000081- Ex 2 000083, Ex 2 000231, Ex 2 000180, Ex 7 000017-Ex 7 000023, Ex 7 000041-Ex 7 000043) Vaccination/Immunization (Bates Ref: Ex 2 000173-Ex 2 000174, Ex 2 000446-Ex 2 000447) | |

Other records (non-medical):

Authorization (Bates Ref: Ex 2 000565-Ex 2 000569, Ex 2 000851-Ex 2 000852, Ex 2 000891-Ex 2 000892, Ex 3 000003-Ex 3 000004, Ex 3 000157-Ex 3 000158, Ex 3 000175-Ex 3 000177, Ex 3 000435-Ex 3 000437, Ex 4 000003-Ex 4 000009, Ex 4 000129-Ex 4 000131, Ex 4 000211-Ex 4 000214, Ex 4 000471-Ex 4 000474, Ex 4 000561-Ex 4 000563, Ex 4 000580-Ex 4 000582, Ex 4 000618-Ex 4 000620, Ex 2 000048, Ex 2 000161-Ex 2 000162)

Blank Pages (Bates Ref: Ex 2 000472-Ex 2 000473)

Patient 1
Patient 2

DOB: MM/DD/YYYY
DOB: MM/DD/YYYY

| DATE | FACILITY/ PROVIDER | MEDICAL EVENTS | BATES REF |
|---|-----------------------|----------------|-----------|
| Coding Sheet (Bates Ref: Ex 4 000591, Ex 4 000606, Ex 3 000048, Ex 4 000096, Ex 4 000132-Ex 4 000134, Ex 3 000139, Ex 3 000246, Ex 3 000371, Ex 1 000018-Ex 1 000019, Ex 2 000902-Ex 2 000903, Ex 2 000624, Ex 2 000640, Ex 2 000604, Ex 2 000445, Ex 2 000223) | | | |
| Consent (Bates Ref: Ex 2 000904-Ex 2 000906, Ex 3 000085-Ex 3 000086, Ex 1 000020- Ex 1 000031, Ex 9 001271-Ex 9 001283, Ex 9 001287, Ex 2 000870) | | | |
| Duplicate (Bates Ref: Ex 2 000603, Ex 2 000564, Ex 2 000026, Ex 4 000665, Ex 4 000607-Ex 4 000614, Ex 2 000923-Ex 2 000924, Ex 2 001062, Ex 9 000394-Ex 9 000395, Ex 2 000474-Ex 2 000483, Ex 2 000698-Ex 2 000708, Ex 9 000160-Ex 9 000165, Ex 5 000038-Ex 5 000043, Ex 2 000726-Ex 2 000735, Ex 4 000128, Ex 4 000470, Ex 4 000560, Ex 4 000579, Ex 4 000590, Ex 4 000605, Ex 4 000617, Ex 4 000664, Ex 2 000496-Ex 2 000497, Ex 2 000721-Ex 2 000722, Ex 4 000004-Ex 4 000005, Ex 2 000751, Ex 5 000017-Ex 5 000019, Ex 2 000659, Ex 8 000109-Ex 8 000111, Ex 8 000121-Ex 8 000124, Ex 2 000416, Ex 2 000392, Ex 2 000363, Ex 2 000343, Ex 2 000289, Ex 6 000002-Ex 6 000003, Ex 2 000179, Ex 2 000058-Ex 2 000061, Ex 2 000002, Ex 4 000564-Ex 4 000576, Ex 4 000592-Ex 4 000602, Ex 4 000670-Ex 4 000702, Ex 2 000776-Ex 2 000786, Ex 5 000118-Ex 5 000127, Ex 8 000106-Ex 8 000108, Ex 2 000712-Ex 2 000720, Ex 2 000724, Ex 2 000738-Ex 2 000750, Ex 2 000697, Ex 2 000605-Ex 2 000606, Ex 2 000627-Ex 2 000628, Ex 2 000644-Ex 2 000645, Ex 2 000931-Ex 2 000932, Ex 2 000222, Ex 2 000273, Ex 2 000253, Ex 2 000224-Ex 2 000227, Ex 2 000079, Ex 2 000074) | | | |
| Fax Sheets (Bates Ref: Ex 2 000068-Ex 2 000069, Ex 2 000071, Ex 2 000498, Ex 2 000510-Ex 2 000511, Ex 2 000723, Ex 2 000725, Ex 2 000675, Ex 2 000677, Ex 2 000736-Ex 2 000737, Ex 2 000073, Ex 2 000105) | | | |
| Legal Documents (Bates Ref: Ex 2 000001, Ex 2 000062-Ex 2 000065, Ex 2 000124-Ex 2 000127, Ex 2 000484-Ex 2 000486, Ex 3 000001, Ex 6 000001, Ex 7 000001, Ex 7 000108-Ex 7 000109, Ex 9 000001, Ex 4 000267-Ex 4 000268, Ex 2 000893-Ex 2 000901, Ex 5 000128-Ex 5 000129, Ex 2 000070) | | | |
| Medical Bills (Bates Ref: Ex 5 000136-Ex 5 000142, Ex 5 000144-Ex 5 000145) | | | |
| Patient's Information (Bates Ref: Ex 2 000888, Ex 4 000093-Ex 4 000094, Ex 4 000126-Ex 4 000127, Ex 4 000208-Ex 4 000209, Ex 4 000558-Ex 4 000559, Ex 4 000588-Ex 4 000589, Ex 4 000603-Ex 4 000604, Ex 4 000615-Ex 4 000616, Ex 4 000662-Ex 4 000663, Ex 4 000002-Ex 4 000003, Ex 2 000635-Ex 2 000636, Ex 2 000619-Ex 2 000620, Ex 2 000601-Ex 2 000602, Ex 2 000441, Ex 2 000220-Ex 2 000221, Ex 2 000158-Ex 2 000159) | | | |